

Original Article

Head-Shaking Nystagmus in the Early Stage of Unilateral Meniere's Disease

Arianna Di Stadio , Giampietro Ricci , Massimo Ralli , Paolo Tropiano, Giovanni Agostini, Mario Faralli 

Department of Otolaryngology, University of Perugia, Perugia, Italy (ADS, GR, TP, GA)

Department of Organ of Sense, University La Sapienza, Rome, Italy (MR)

Department of Otolaryngology, Silvestrini Hospital, Perugia, Italy (MF)

ORCID IDs of the authors: A.D.S. 0000-0001-5510-3814; G.R. 0000-0001-9819-113X; M.R. 0000-0001-8776-0421; M.F. 0000-0002-3634-1865.

Cite this article as: Di Stadio A, Ricci G, Ralli M, Tropiano P, Agostini G, Faralli M. Head-Shaking Nystagmus in the Early Stage of Unilateral Meniere's Disease. J Int Adv Otol 2019; 15(3): 425–30.

OBJECTIVES: The aim of the present study was to evaluate the ability of head-shaking nystagmus (HSNy), evoked after the resolution of a vertigo spell, to predict an imminent crisis in the early stage of Meniere's disease (MD).

MATERIALS and METHODS: A total of 20 patients in the early stage of MD were included in the study. The head-shaking test (HST) was performed twice, during the first visit within 24 h of vertigo spell (T0) and 48 h later (T1). The onset of a new vertigo episode during the 2 weeks following the first visit was recorded in each patient's medical record. The sensitivity and specificity of HSNy toward predicting a new vertigo episode were calculated.

RESULTS: At T0, an evoked ipsilesional HSNy in 15 (75%) patients was observed; in four of them, the HSNy had a biphasic component. The HSNy was present and persistent at T1 in 8 (42.1%) patients; among these cases, 6 patients had ipsilesional HSNy, and 2 patients a contralesional HSNy. None of the patients presented with a biphasic HSNy at T1. Seven (36.8%) patients experienced the recurrence of a vertigo crisis. Among these, 6 patients had ipsilesional HSNy at T1. Only 8 patients with ipsilesional HSNy at T0 did not have recurrence. The sensitivity of the ipsilesional HSNy in predicting the recurrence of vertigo in patients with MD was 100% at T0 and 85.7% at T1. The specificity was 46.6% and 100% at T0 and T1, respectively.

CONCLUSION: The HST can be a useful test in the early stages of MD to predict a new vertigo attack.

KEYWORDS: Head-shaking test, Meniere's disease, head-shaking nystagmus, predictive value, imminent crisis

INTRODUCTION

The head-shaking test (HST) is a simple technique that clinicians can easily perform to identify dynamic asymmetry in the vestibulo-ocular reflex. Patients with a unilateral vestibular lesion show, after the resolution of spontaneous nystagmus, a new transient nystagmus. In these patients, the transient nystagmus is induced by rapid head shaking (10–20 cycles) performed in the yaw plane [1–3]; this nystagmus is referred to as head-shaking nystagmus (HSNy). The regulation of HSNy follows an analytic model that involves a central velocity-storage mechanism for sustaining the vestibular inputs, the principle of Ewald's second law, and the adaptation of primary vestibular afferent activity [1, 4]. A prolonged, lower-amplitude reversal phase can be also detected after the initial response following the horizontal head shaking (biphasic) [1, 4]. An HSNy that beats toward the healthy ear observed in patients affected with unilateral peripheral lesions is a common deficiency-type nystagmus; instead, an HSNy that beats toward the affected ear in patients with unilateral peripheral lesions may be identified as a recovery or irritative-type nystagmus [5]. This test can be used in patients who suffer from Meniere's disease (MD); in this case, the HSNy can be both of deficiency or irritative-type depending on the stage of the disease [6]. Furthermore, a "perverted" HSNy (a nystagmus in a plane other than that being stimulated) in MD has been observed; in this case, the nystagmus presents a vertical component [7, 8].

MD is a disease that affects the inner ear characterized by an endolymphatic hydrops [9–11]. The hydrops, triggered by environmental factors, such as virus or vasoconstriction, that in genetic predisposed subjects can determine an increased immunity response to

these factors^[12–14], is generally temporary (between 20 min and few hours) and determines a series of audiovestibular symptoms, such as vertigo, tinnitus, fullness, and hearing loss^[9, 10, 15]. Recently, researchers have identified a correlation between the presence of migraine and MD^[16]; probably, in these cases, the effect of vasoconstriction (very common in migraine episodes) may be the cause of the MD crisis. The MD crisis can have a spontaneous resolution especially in the first year of affection, but in most cases requires pharmacological treatment^[9, 10]. Anyway, the best method to limit the severity of the crisis is its prevention^[9, 10].

Although performing vestibular clinical examination in patients affected with MD may lead to variable observational findings^[17–20], abnormal results are easily observable using vestibular tests that generate objective findings for the identification of HSNy, followed by the vibration-induced nystagmus (VIN) and the caloric test^[19]. Some authors observed that an irritative-type HSNy may be indicative of the recurrence of a crisis within a very short time^[21]. Furthermore, the presence of an HSNy directed to the affected ear observed during the MD recovery period might indicate the oncoming recurrence of a vertigo attack within a few days^[8, 22].

We hypothesize that in the first stages of MD, there is a complete vestibular functional recovery after the attack due to the transition of the hydrops. Furthermore, patients in the early stage of MD do not have permanent damage of the vestibular receptors, typical of the more advanced stages. Taken together, in the early stage of MD, we expect to observe a purely dysfunctional HSNy. Based on these hypothesis and previous findings, the aim of the present study was to evaluate the prognostic value of HSNy for the prediction of an imminent vertigo attack in patients affected by MD by performing a qualitative evaluation of HSNy immediately after the resolution of an attack in a sample of patients recently diagnosed with early-stage MD.

MATERIALS AND METHODS

Study design

This was a longitudinal, unicenter prospective study conducted in the vestibular center of our university hospital between February 2015 and September 2018. The study was approved by the institutional review board commission of the university hospital without releasing an identification number, following national law, in accordance with the Declaration of Helsinki. All subjects signed a written consent before being included in the study.

Patient enrollment

All patients aged between 18 and 65 years lamenting an episode of vertigo that occurred within 24 h of consultation were consecutively evaluated. All patients underwent clinical history collection, clinical observation for spontaneous and positional nystagmus, otomicroscopy, and pure tone audiometry (PTA). The following vestibular tests were performed: HST, head impulse test (HIT), VIN at 100 Hz, subjective visual vertical (SVV), cervical vestibular-evoked muscular potentials (c-VEMPs), and caloric test. The patients were observed at three time points: within 24 h of vertigo onset (T0), after 48 h (T1), and after 14 days (T2). Specifically, at T0, the patients underwent PTA, HST, VIN, SVV, and c-VEMPs but not to caloric test and HIT. At T1, the patients were investigated with all vestibular tests. At T2, the patients

repeated PTA evaluation. All patients were invited to complete a clinical daily diary detailing the recurrence of new vertigo spells. Pharmacological treatment with 48 mg of beta-histidine (24 mg two times daily) was initiated at T0 in all patients.

Inclusion criteria was a diagnosis of unilateral definitive early-stage MD (<6 months) according to the Barany Society criteria^[23] with a maximum of three vertigo episodes during the last 6 months. In details, diagnosis was based on clinical history and audiovestibular examination; patients with (1) two or more episodic vertigo syndromes limited to a period of 20 min to 12 h, associated with (2) low- to medium-frequency sensorineural hearing loss (SNHL) identified in at least one observation, and (3) fluctuating aural symptoms (hearing, tinnitus, and/or fullness) in one ear were classified as unilateral definitive MD and were included in the study.

Exclusion criteria were as follows: patients who did not fully meet the diagnostic criteria for MD, had a clinical diagnosis of bilateral MD, a history of MD of >6 months, middle ear pathology, or other forms of vertigo due to neurological disorders, affected by migraine or other known vestibular disorders, or with familial history of MD. Additionally, patients classified as definitive MD with persistent spontaneous nystagmus were excluded because the presence of a spontaneous nystagmus is indicative of static vestibular asymmetry. Patients who presented with a new vertigo episode between the first (T0) and the second (T1) observation were also excluded from the study.

Pure tone audiometry

All patients underwent PTA at T0 and T2. PTA was measured at frequencies of 250, 500, 1000, 2000, 3000, 4000, and 8000 Hz; data at frequencies of 500, 1000, 2000, 3000, and 4000 Hz were used in the study.

Head-shaking test

HST was performed at T0 and T1. The patient was seated, and the physician flexed his/her head (nose directed down) by 30°; the head was passively rotated horizontally by $\pm 45^\circ$ at 1 Hz for 20 s, followed by electro-oculograph recording looking for an evoked nystagmus. Transient nystagmus was observed after rapidly shaking the head when a vestibular imbalance occurred. HSNy was considered pathologic when, by shaking the head, it appeared for at least two clear post-rotation horizontal nystagmic beats with a peak slow phase eye velocity over $5^\circ/\text{s}$ ^[8, 24]. HSNy was classified as monophasic (single phase) or biphasic (two phases) and then, as a function of the ear affected with the disease, was defined as ipsilesional (nystagmus directed to the same side as the affected ear) or contralesional (nystagmus directed to the healthy ear). In case of a biphasic HSNy, the first component (first phase of nystagmus) defined if this was ipsilesional or contralesional^[1–4, 8]. To achieve the aim of the present study, only the horizontal component of the nystagmus and not the concomitant vertical or torsional components was evaluated.

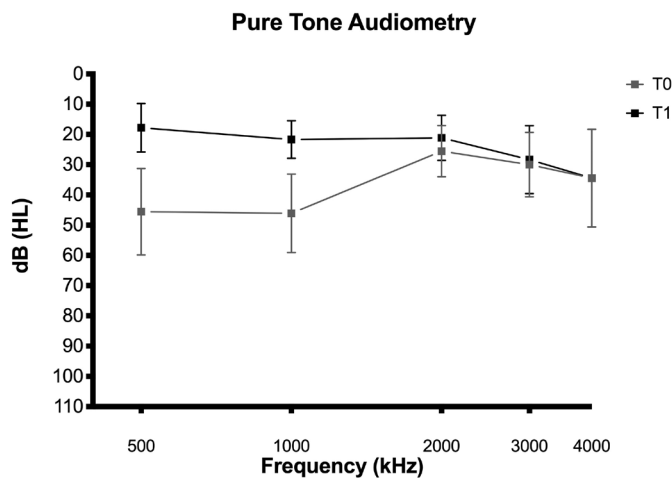
Statistical Analysis

The odds ratios (ORs) in patients with ipsilesional HSNy and the sensitivity and the specificity of the HSNy toward the prediction of a new, imminent vertigo attack were calculated using Stata® (www.stata.com). A p-value <0.05 was considered statistically significant.

Table 1. Summary of data related to patients recruited in the study: Type of head-shaking nystagmus at head-shaking test performed at T0 (within 24 hours from the vertigo spell) and T1 (within 48 hours) and daily trend of new crisis during the follow up (14 days)

Patients	Sex	Age	1° HST (T0)	2° HST (T1)	Follow-up (14 days)														Crisis	
					1	2	3	4	5	6	7	8	9	10	11	12	13	14	T2	
1	F	41	Ipsi (monoph)	Ipsi (monoph)			X												Yes	
2	M	55	Ipsi (biphasic)	Absent															Not	
3	F	36	Ipsi (biphasic)	Contra (monoph)															Not	
4	F	40	Absent	Absent															Not	
5	F	64	Ipsi (monoph)	Ipsi (monoph)				X											Yes	
6	M	60	Ipsi (monoph)	Absent													X		Yes	
7	M	48	Ipsi (monoph)	Absent															Not	
8	F	43	Absent	Absent															Not	
9	M	41	Ipsi (monoph)	Ipsi (monoph)	X														Yes	
10	M	57	Ipsi (monoph)	Ipsi (monoph)					X										Yes	
11	F	60	Absent	Absent															Not	
12	M	52	Ipsi (biphasic)	Absent															Not	
13	F	62	Ipsi (monoph)	Contra (monoph)															Not	
14	F	43	Ipsi (monoph)	Absent															Not	
15	M	28	Ipsi (monoph)	Ipsi (monoph)	X														Yes	
16	M	55	Absent	Absent															Not	
17	F	52	Ipsi (biphasic)	Absent															Not	
18	M	63	Ipsi (monoph)	Ipsi (monoph)							X								Yes	
19	F	39	Ipsi (monoph)	Absent															Not	

Ipsi: ipsilesional head-shaking nystagmus; Contra: contralesional head-shaking nystagmus; Monoph: monophasic head-shaking nystagmus; Biph: biphasic head-shaking nystagmus. X indicates the day of the onset of the first new crisis during follow-up.

**Figure 1.** Pure tone audiometry thresholds for patients included in the study at T0 and T2.

RESULTS

Initial visit (T0—within 24 h after vertigo attack)

A total of 20 (11 female and 9 male) subjects were included in the study. The average age of the patients was 49.4 years (standard de-

viation 10.4, 95% confidence interval (CI): 36-62). All patients had unilateral SNHL on the same side of the MD. The PTA evidenced an auditory threshold indicative of low or mild SNHL especially for low frequencies. The average PTA was 45.6 dB at 500 Hz, 46.1 dB at 1000 Hz, 25.6 dB at 2000 Hz, 30 dB at 3000 Hz, and 34.4 dB at 4000 Hz (Figure 1).

The HST performed within 24 h of vertigo onset showed that 16 (80%, 8 male and 8 female) patients presented with an ipsilesional HSNy, whereas 4 (20%) subjects did not present with HSNy. In patients with ipsilesional HSNy, 4 (25%) subjects were affected with a biphasic HSNy, and the remaining 12 (75%) subjects were affected with a monophasic form.

Second visit (T1—48 h after vertigo attack)

At T1, the patients underwent HST and a complete vestibular test battery. Nineteen (95%) patients observed at T0 were re-tested at T1. One subject, who presented an ipsilesional HSNy at T0, suffered from a vertigo episode between the first and the second follow-up and was excluded from the second HST according to our inclusion/exclusion criteria.

Eight (42.1%, 4 male and 4 female) patients presented with an HSNy after the HST. Six (75%) patients presented with an ipsilesional HSNy,

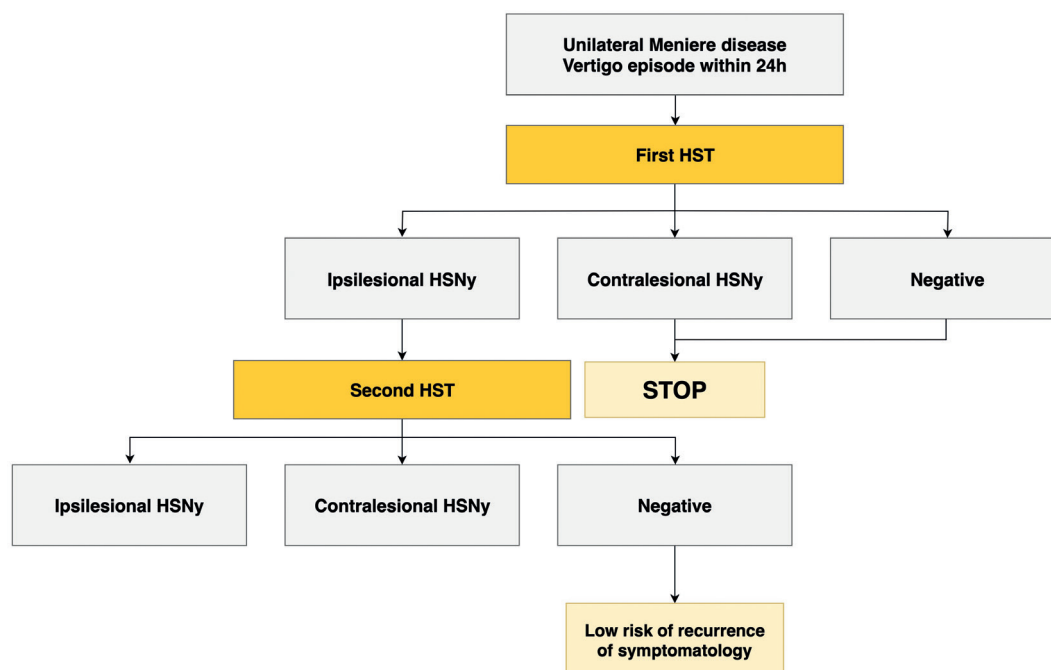


Figure 2. Proposal of an algorithm for identifying a patient at risk of a new vertigo attack using the head-shaking test.

and 2 (25%) patients showed a contralesional HSNy. For the eight patients who presented with an HSNy, the VIN was the only test out of the normal range results and, therefore, indicative of a vestibular imbalance. Specifically, we observed a case in which both the VIN and the HSNy were ipsilateral. The VIN was directed to the healthy side in three cases; the results of the HST showed an ipsilesional HSNy in two subjects and a contralesional one in one case. None of the 11 patients in whom the HSNy was not evocable after the HST presented altered results in the other vestibular tests.

Third visit (T2—14 days after vertigo attack)

At T2, the patients performed a new PTA to evaluate hearing recovery, and the evaluation of the clinical diary of vertigo spells occurred between T1 and T2.

The average PTA was 17.8 dB at 500 Hz, 21.7 dB at 1000 Hz, 21.1 dB at 2000 Hz, 28.3 dB at 3000 Hz, and 34.4 dB at 4000 Hz with a significant improvement for low frequencies, whereas no changes were observed for mid and high frequencies.

Seven (36.8%) out of the 19 patients re-evaluated at T1 presented with a new vertigo episode during the observational period. All of these subjects had an ipsilesional HSNy at T0 that persisted at T1 in 6 (85.7%) cases. In one case, we observed a recurrence of vertigo in a subject in whom the HSNy was absent at T1. Details on the timing of the onset of a new crisis are presented in Table 1. On the contrary, we did not observe a new crisis in any of the eight patients with an absence of HSNy at T1, even in patients with an HSNy at T0. This sample of patients also included subjects who presented with a biphasic HSNy. Patients with an ipsilesional HSNy after 48 h had an OR of 108.3333 (95% CI: 3.8465-3051.1313) with a statistically significant increased risk ($p < 0.005$) of developing a new crisis within 15 days. The sensitivity of ipsilesional HSNy toward predicting the short-

term recurrence of a new attack was 100% and 85.7% at T0 and T1, respectively, and the specificity was 46.6% and 100% at T0 and T1, respectively.

DISCUSSION

The results of our study show that patients with MD present with an increased rate of ipsilesional HSNy in the early stages of the disease, as also shown by other authors [24, 25]. Furthermore, when this is evoked 48 h after a recent vertigo spell, these patients have an increased risk of developing a new MD attack within 15 days.

In 1995, Kamei [5] investigated the predictive value of HSNy in patients affected with MD as an early indicator of a new crisis. He analyzed a sample of eight patients with MD and observed that the presence of an ipsilesional HSNy during the intercritical phase (recovery period between two MD crises) correlated with the onset of a new crisis between 6 h and 8 days (mean=3.2 days) [24]. Our results are consistent with those reported by Kamei; however, we also observed additional findings. First, we noted the absence of a contralesional-type HSNy in the immediate post-crisis period, and that only the ipsilesional HSNy was evoked; this finding is representative of a functional state related in time to the crisis and the length of the affliction (duration of illness). This result may be correlated to the state of the illness in the patients included in our study; in fact, if they were diagnosed as definitive MD during the first clinical evaluation (T0), the vestibular organ likely had limited damage, and the patients may recover their vestibular function quite well after the crisis. This idea was confirmed by the results of the HIT, SVV, caloric, and c-VEMP tests and partially confirmed by the VIN findings that showed a selective, high-frequency imbalance in a minority of cases. Second, we observed, as a frequent finding in our sample, the presence of transient reversed nystagmus (biphasic) in the phases immediately after the vestibular crises. We speculate that this nystagmus may be the expression of a

variable vestibular functional state and reflective of the quick activation of adaptive vestibular mechanisms.

The most relevant result of our study is the determination of the increased risk of developing a new crisis in a very short period (<14 days), as observed in patients with MD, when an ipsilesional HSNy is evoked within 48 h from the crisis. Furthermore, this finding was highly sensible and specific at both the initial visit (100% and 46.6%) and 48 h later (85.7% and 100%). In particular, 48 h after the crisis, the sensibility was associated with high specificity (100%) by confirming the validity of the HSNy at this time point. In fact, we observed six patients with this positive finding that presented with a new short-term crisis within 2-10 days. This finding likely represents a real persistent irritative HSNy.

In eight patients, we observed an ipsilesional HSNy at T0 only, and we considered this to be a recovery HSNy; unfortunately, at this observational point, this finding was associated with lower specificity than the one observed at T1 (46.6% and 100%, respectively).

Finally, we identified a normal HST (i.e., without an HSNy) in one patient who presented with a recurrence of a vertiginous crisis at T2. In this patient, the interval time between T1 and the new crisis was extremely long (14 days) compared with the recurrence times observed in patients who presented with an abnormal response at HST (ipsilesional HSNy) (<8 days); therefore, we did not consider the recurrence of vertigo in this single case to be a "very imminent event." In addition, the majority of patients in our sample presented with a new vestibular crisis within 5 days from T1, and in these cases, the HSNy was very sensible (87.5%) and extremely specific (100%). We recorded an ipsilesional HSNy at T0 in the seven cases who then developed new crises; six of the seven patients with an initial ipsilesional HSNy presented with the same finding at T1. The persistence of this observation can suggest a group of patients strongly at risk of an imminent relapse of vertigo.

Additionally, we identified the presence of a biphasic HSNy at T0 in four patients, and this appears to be a favorable predictive element. Furthermore, even if the contralesional HSNy does not appear to be a functional state characteristic of the early stages of MD immediately after the crisis, we observed this finding in two cases 48 h after the crisis. We hypothesize that this may be the expression of a later adaptive process similar to the biphasic HSNy evoked after the first HST or may represent the initial subclinical, persistent damage to the vestibular receptors. In these cases, evoking a contralesional HSNy at this stage does not appear to predict a new crisis in the following days.

To reinforce the predictive value of HSNy, it is relevant to underline that none of the four patients with normal HST at the initial visit and 48 h later (without HSNy) presented with a new vertiginous crisis within 14 days. For these cases (absence of positive findings in HST), we suggest that a short-term control with HST is not necessary. On the contrary, when an ipsilesional HSNy is identified and in the absence of spontaneous nystagmus, we recommend the repetition of HST within 48 h of the crisis (Figure 2).

In 1999, Kamei ^[24] reported that the immediate administration of an osmotic diuretic when an ipsilesional HSNy is observed successfully

suppresses the recurrence of vertigo in three out of eight patients ^[24,25]. While we did not verify this in our study, a targeted therapeutic approach may be designated in high-risk patients following our suggested algorithm.

Even though additional studies with larger sample sizes are necessary to confirm our preliminary results, our results are promising and clinically relevant because they suggest that the correct follow-up in the days immediately following the crisis can potentially optimize the therapeutic approach.

Our study has some limitations. These limitations include the small sample size, the absence of a healthy control group, and the absence of distortion product otoacoustic emission and auditory brainstem response evaluation in enrolled patients.

CONCLUSION

We observed that the presence and persistence of an ipsilesional HSNy at different time points in patients with unilateral MD may be predictive of a new imminent crisis within 7 days of the second follow-up visit. These patients also present an increased risk for a short recurrence of a new vertigo attack. Owing to the simplicity of the execution of the HST and the high predictive value that we observed in our patients, we recommend its use following our clinical algorithm to monitor the possibility of a new crisis and to start in high-risk patients an early pharmacological treatment to reduce the number of new vertigo attacks. Additional studies are necessary to evaluate HSNy in the more advanced stages of the disease and to determine if its predictive value in identifying a new imminent crisis may be similar to that observed in patients with an early confirmed diagnosis of MD.

Ethics Committee Approval: Ethics committee approval was received for this study from the Ethics Committee of Silvestrini Hospital.

Informed Consent: Written informed consent was received from the patients who participated in this study.

Peer-review: Externally peer-reviewed.

Author Contributions: Concept – M.F., A.D.S.; Design – A.D.S., M.F.; Supervision – G.R.; Resource – M.F.; Materials – A.D.S., M.F.; Data Collection and/or Processing – A.D.S., P.T., G.A., M.R.; Analysis and/or Interpretation – M.F., A.D.S.; Literature Search – M.R.; Writing – A.D.S., M.F., M.R.; Critical Reviews – G.R., P.T., G.A.

Acknowledgements: Thanks to all patients for their participation.

Conflict of Interest: The authors have no conflict of interest to declare.

Financial Disclosure: The authors declared that this study has received no financial support.

REFERENCES

1. Hain TC, Fetter M, Zee DS. Head-shaking nystagmus in patients with unilateral peripheral vestibular lesions. *Am J Otolaryngol* 1987; 8: 36-47. [\[CrossRef\]](#)
2. Panichi R, Faralli M, Bruni R, Kiriakarely A, Occhigrossi C, Ferraesi A, et al. Asymmetric vestibular stimulation reveals persistent disruption of motion perception in unilateral vestibular lesions. *J Neurophysiol* 2017; 118: 2819-32. [\[CrossRef\]](#)

3. Zuma EMFC, Cal R, D'Albora R, Carmona S, Schubert MC. Head-shaking tilt suppression: a clinical test to discern central from peripheral causes of vertigo. *J Neurol* 2017; 264: 1264-70. [\[CrossRef\]](#)
4. Kamei T. [The two-phase occurrence of head-shaking nystagmus (author's transl)]. *Arch Otorhinolaryngol* 1975; 209: 59-67. [\[CrossRef\]](#)
5. Kamei T, Takegoshi T, Matsuzaki M. A quantitative analysis of head-shaking nystagmus of peripheral vestibular origin. *Acta Otolaryngol Suppl* 1995; 520 Pt 1: 216-9. [\[CrossRef\]](#)
6. Kamei T. Two types of head-shaking tests in vestibular examination. *Acta Otolaryngol Suppl* 1988; 458: 108-12. [\[CrossRef\]](#)
7. Kim CH, Shin JE, Kim TS, Shim BS, Park HJ. Two-dimensional analysis of head-shaking nystagmus in patients with Meniere's disease. *J Vestib Res* 2013; 23: 95-100. [\[CrossRef\]](#)
8. Perez P, Llorente JL, Gomez JR, Del Campo A, Lopez A, Suarez C. Functional significance of peripheral head-shaking nystagmus. *Laryngoscope* 2004; 114: 1078-84. [\[CrossRef\]](#)
9. Gurkov R, Pyyko I, Zou J, Kentala E. What is Meniere's disease? A contemporary re-evaluation of endolymphatic hydrops. *J Neurol* 2016; 263 Suppl 1: S71-81. [\[CrossRef\]](#)
10. Nakashima T, Pyykko I, Arroll MA, Casselbrant ML, Foster CA, Manzoor NF, et al. Meniere's disease. *Nat Rev Dis Primers* 2016; 2: 16028. [\[CrossRef\]](#)
11. Espinosa-Sanchez JM, Lopez-Escamez JA. Meniere's disease. *Handb Clin Neurol* 2016; 137: 257-77. [\[CrossRef\]](#)
12. Frejo L, Martin-Sanz E, Teggi R, Trinidad G, Soto-Varela A, Santos-Perez S, et al. Extended phenotype and clinical subgroups in unilateral Meniere disease: A cross-sectional study with cluster analysis. *Clin Otolaryngol* 2017; 42: 1172-80. [\[CrossRef\]](#)
13. Ralli M, D'Aguanno V, Di Stadio A, De Virgilio A, Croce A, Longo L, et al. Audiovestibular Symptoms in Systemic Autoimmune Diseases. *J Immunol Res* 2018; 2018: 5798103. [\[CrossRef\]](#)
14. Russo FY, Ralli M, De Seta D, Mancini P, Lambiase A, Artico M, et al. Autoimmune vertigo: an update on vestibular disorders associated with autoimmune mechanisms. *Immunol Res* 2018; 66: 675-85. [\[CrossRef\]](#)
15. Mancini P, Atturo F, Di Mario A, Portanova G, Ralli M, De Virgilio A, et al. Hearing loss in autoimmune disorders: Prevalence and therapeutic options. *Autoimmun Rev* 2018; 17: 644-52. [\[CrossRef\]](#)
16. Ray J, Carr SD, Popli G, Gibson WP. An epidemiological study to investigate the relationship between Meniere's disease and migraine. *Clin Otolaryngol* 2016; 41: 707-10. [\[CrossRef\]](#)
17. Kim MB, Huh SH, Ban JH. Diversity of head shaking nystagmus in peripheral vestibular disease. *Otol Neurotol* 2012; 33: 634-9. [\[CrossRef\]](#)
18. Lee SU, Kee HJ, Sheen SS, Choi BY, Koo JW, Kim JS. Head-shaking and Vibration-induced Nystagmus During and Between the Attacks of Unilateral Meniere's Disease. *Otol Neurotol* 2015; 36: 865-72. [\[CrossRef\]](#)
19. Asawavichiandi S, Fujimoto M, Mai M, Desroches H, Rutka J. Significance of head-shaking nystagmus in the evaluation of the dizzy patient. *Acta Otolaryngol Suppl* 1999; 540: 27-33. [\[CrossRef\]](#)
20. Dumas G, Lavieille JP, Schmerber S. [Vibratory test and head shaking test and caloric test: a series of 87 patients]. *Ann Otolaryngol Chir Cervicofac* 2004; 121: 22-32. [\[CrossRef\]](#)
21. Shin JE, Kim CH, Park HJ. Vestibular abnormality in patients with Meniere's disease and migrainous vertigo. *Acta Otolaryngol* 2013; 133: 154-8. [\[CrossRef\]](#)
22. Marques PS, Perez-Fernandez N. Bedside vestibular examination in patients with unilateral definite Meniere's disease. *Acta Otolaryngol* 2012; 132: 498-504. [\[CrossRef\]](#)
23. Lopez-Escamez JA, Carey J, Chung WH, Goebel JA, Magnusson M, Mandala M, et al. [Diagnostic criteria for Meniere's disease. Consensus document of the Barany Society, the Japan Society for Equilibrium Research, the European Academy of Otolology and Neurotology (EAONO), the American Academy of Otolaryngology-Head and Neck Surgery (AAO-HNS) and the Korean Balance Society]. *Acta Otorrinolaringol Esp* 2016; 67: 1-7. [\[CrossRef\]](#)
24. Kamei T, Iizuka T. Prediction of vertigo recurrences in Meniere's disease by the head-shaking test. *Int Tinnitus J* 1999; 5: 47-9.
25. Lopez-Escamez JA, Carey J, Chung WH, Goebel JA, Magnusson M, Mandala M, et al. Diagnostic criteria for Meniere's disease. *J Vestib Res* 2015; 25: 1-7. [\[CrossRef\]](#)