

Case Report

A Message from a Narrowed Internal Auditory Canal in a Patient with a Hyperpneumatized Petrous Bone

Pierre Reynard , Eugen Ionescu , Aïcha Ltaief-Boudrigua , Hung Thai-Van 

Department of Audiology and Otoneurological Evaluation – Lyon University Hospital, Lyon, France (PR, EI, HTV)

Claude Bernard Lyon 1 University, Lyon, France (PR, HTV)

Paris Hearing Institute, Institut Pasteur, Paris, France (PR, EI, HTV)

Department of Radiology, Lyon University Hospital, Lyon, France (ALB)

ORCID iDs of the authors: P.R. 0000-0001-5901-4392; E.I. 0000-0003-3773-9848; A.L.B. 0000-0002-0411-9901; H.T.V. 0000-0002-6647-7640.

Cite this article as: Reynard P, Ionescu E, Ltaief-Boudrigua A, Thai-Van H. A Message from a Narrowed Internal Auditory Canal in a Patient with a Hyperpneumatized Petrous Bone. J Int Adv Otol 2020; 16(3): 484-6.

Hyperpneumatization of the temporal bone (HPTB) is a rare finding, and its clinical impact is poorly described in literature. We report the case of a 34-year-old woman with no previous otologic condition, complaining of paroxysmal vertigo and right pulsatile tinnitus shortly after a first scuba diving session. Clinical neurotologic assessment found a right vestibular impairment. Cranial tomodensitometry showed a bilateral hyperpneumatization of the petrosal air cell system. Brain magnetic resonance imaging to rule out any retrocochlear pathology was normal, although the cochleo-vestibular nerve (CVN) appeared to be over lengthened in a narrowed internal auditory canal (IAC), especially on the right-hand side. Pain was alleviated by administration of a low-dose anti-epileptic drug. The clinical, neurological, and radiological findings evoked a right vestibulopathy generated by a limited compression of the CVN; HPTB appeared to contribute to the narrowing of the IAC, especially on the right-hand side.

KEYWORDS: Temporal bone diagnostic imagery, vestibular nerve, ear canal pathology

INTRODUCTION

Hyperpneumatization of the temporal bone (HPTB) is mainly described and classified on the basis of tomodensitometric aspects^[1]. It is widely accepted that air cell system of the petrous bone serves as an air reservoir for the middle ear in case of Eustachian tube dysfunction^[2]. The pneumatization process of the temporal bone starts after birth and is completed around the age of 10 years. It is achieved by the transition of the temporal bone into air cells, starting from the area adjacent to the middle ear cavity and the antrum mastoideum during the embryonic period^[2]. Size of the air cells is thought to be genetically or environmentally determined^[1]. The clinical impact of HPTB is poorly described.

In this paper, we report clinical and audio-vestibular findings in a patient with important HPTB experiencing tinnitus and vertigos after practicing her first scuba diving session.

CASE PRESENTATION

A 34-year-old patient with no previous medical history consulted her physician for vertigos and complained of constant right ear fullness, which appeared shortly after practicing her first scuba diving session. The patient had dived for the first time, and had been bothered right from the initial meters by otalgia. She came back quickly to the surface in less than 2 minutes.

Three days later, spontaneous vertigos disappeared, but the patient still complained of short-lasting gait instability. One week later, video head impulse test (VHIT, Ulmer II, Marseille, France) performed by her physician showed reduced gain concerning posterior and lateral semi-circular canals on the right-hand side, and a spontaneous horizontal left nystagmus was observed under videonystagmoscopy (VNS) mask.

The patient was referred to our neurotologic unit. Upon clinical examination, the main symptom was a sensation of pressure in both ears, exacerbated by decubitus on the right-hand side and by cautious Valsalva maneuvers (VM). The patient also complained of a recent moderate right pulsatile tinnitus and episodic vertigo. Otomicroscopic evaluation, pure tone audiometry, and speech audiometry results were normal.

At initial assessment by VNS, a right horizontal spontaneous and irritative nystagmus was observed. Hennebert sign was absent, and cautious tympanometry did not reveal any change of the nystagmus. The nystagmus was accelerated by a hyperventilation test in dor-

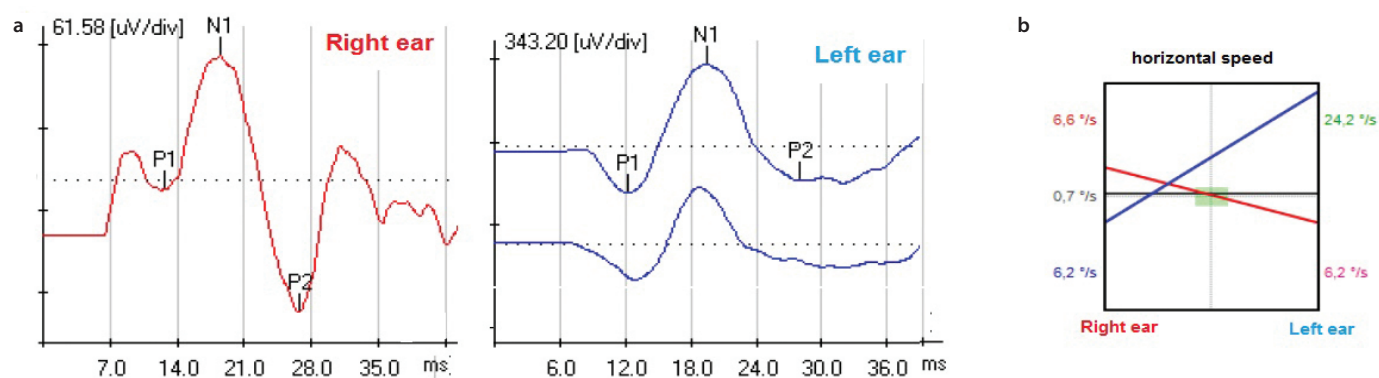


Figure 1. a, b. a) Bithermal caloric tests: moderate right canal paresis (41%) and right directional preponderance. b) Amplitude reduced cervical vestibular evoked myogenic potentials in air conduction elicited by 750 Hz-tone bursts, on the right-hand side (90 microvolts VS 490 on the left-hand side) at 90 dB HL.

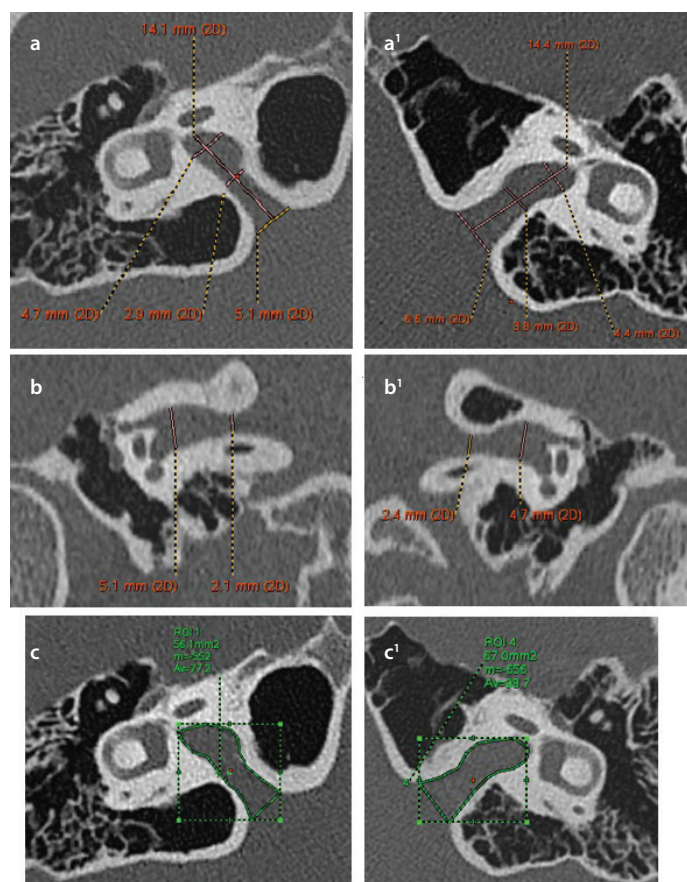


Figure 2. a-c. Temporal bone high-resolution computed tomography (HRCT) in axial plane showing hyperpneumatization of the petrous bone at the level of IAC. a) and a') (right- and left-hand sides): hyperpneumatized IAC walls; prolonged IAC length of 14.1 mm on the right-hand side and 14.4 mm on the left-hand side. b) and b') (right- and left-hand sides): HRCT coronal plane. Bilateral IAC stenosis. Significantly reduced porus IAC height: 2.1 mm on the right-hand side and 2.4 mm on the left-hand side. c) and c') (right- and left-hand sides): HRCT axial plane. IAC areas normal or slightly increased.

sal decubitus^[3]. The skull 100 Hz vibration test generated an inversion of the initial nystagmus, resulting in a rightward-moving quick phase. Dix-Hallpike maneuvers for benign paroxysmal positional vertigo were negative, and the patient was free of neurological signs.

Videonystagmography showed normal vestibulo-ocular response (VOR) gain on rotatory chair. A moderate right canal paresis (41% ac-

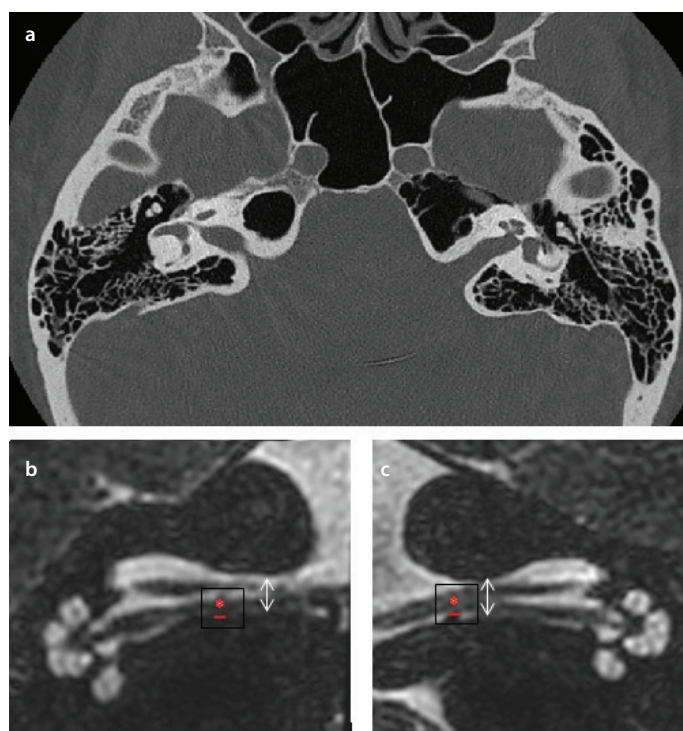


Figure 3. a-c. a) Temporal bone high-resolution computed tomography (HRCT) in axial plane showing hyperpneumatization of the petrous bone at the level of IAC. b) and c) T2 weighted HR DRIVE (3T MRI, Ingenia, Philips) Reduced vertical diameters (white arrow) of both IAC (a) right-hand side; b) left-hand side. Red cross: cochleo-vestibular nerve in direct contact on more than 3.6 mm with the inferior wall of the IAC. Note that only a slight and limited contact was found on the left-hand side.

cording to Jongkees' formula) associated with a right directional preponderance was detected by bithermal caloric tests. VHIT (Otometrics, Denmark) found normal gains for all semicircular canals, except for the right posterior canal, in which the VOR gain was very low (0.2), associating with consistent covert saccades. Cervical vestibular evoked myogenic potentials (cVEMPs) in air conduction elicited by 750 Hz-tone bursts with controlled muscular (sterno-cleido-mastoidian) contraction, were bilaterally present at 90 dB HL with normal latencies and amplitudes on the left-hand side (490 microvolts) but with reduced amplitudes on the right-hand side (90 microvolts) (Figure 1). Auditory brainstem response at 80 dB HL showed a normal pattern bilaterally.

Cranial high-resolution computed tomography (HRCT; Figures 1, 2 and 3a) showed an important bilateral hyperpneumatization of

the skull base. More specifically, at the IAC level, bilaterally, the air cells were largely expanded, generating distortion of the IAC walls. Medial halves of both IACs were narrowed. IACs were stretched and longer than normal, measured at 14 mm on the right-hand side and 14.4 mm on the left-hand side (reference: 9.84 mm) ^[4]. Regarding the antero-posterior diameters, at IAC mid-distance, diameter was measured at 2.9 mm on the right-hand side and 3.8 mm on the left-hand side (reference: 4.4 mm at the same level) ^[4]. No other anomalies of the middle or inner ear structures were observed.

Magnetic resonance imaging (MRI, Philips healthcare, Amsterdam, Netherlands) ruled out other pathologies of the inner ear, IAC, and related structures but confirmed the presence of a narrowed and stretched IAC. A compressive effect on the right cochleo-vestibular nerve (CVN) was suspected (Figure 3b, c). Angio MRI T2 DRIVE (Philips healthcare, Amsterdam, Netherlands) sequences ruled out neurovascular cross compression, which could have explained pulsatile tinnitus.

On the basis of these clinical and radiological findings, a right vestibulopathy due to a limited compression of the CVN was evoked. The symptoms having started after immersion and being aggravated by VM, the practice of scuba diving was strongly discouraged to the patient.

As recommended by the Barany Society ^[5] in case of suspicion of audio-vestibular paroxysmia (VP) by a cross-compression syndrome of the CVN, a treatment with oxcarbazepine (Novartis, Bâle, Suisse) 300 mg a day for one month was proposed as a trial. Vestibular symptoms gradually improved, and pulsatile tinnitus disappeared. Six months after gradually tapering the medication, the patient complained only of short-lasting vertigos while turning the head rapidly toward the right direction. Spontaneous nystagmus disappeared but was still evoked by hyperventilation. During follow-up, the VHIT gain in the right posterior canal improved slightly but remained decreased (0.4).

DISCUSSION

Isolated HPTB has been reported as a possible etiology in subjective tinnitus ^[6]. An increased resonance, as described in case of HPTB, would favor an excessive transmission of sounds from normal vessels to cochlea, even in the absence of any non-laminar blood flow ^[7]. In the case presented here, large air cells between IAC and cochlea would serve as an amplifier. However, radiological measures also indicated a bilateral narrowed and stretched IAC.

Middle ear barotrauma alone could not explain the entire symptomatology—including findings during hyperventilation test—and there were no evocative findings upon otomicroscopy, nor any audiogram or tympanometric abnormalities. Alternobaric vertigo (AV) is the most common cause of transient vertigo while diving and is generated from an insufficient equalization of gaseous pressure exerted via oval and round window membranes ^[8]. However, AV is transient, can last only several minutes, and is often accompanied by nausea, vomiting, and disorientation, symptoms that did not occur herein during immersion. Instead, neurotological findings indicated a right and recent vestibular impairment, which corresponds clinically to a compression of the right CVN in a narrowed IAC. In our opinion, the significant HPTB observed in this case report should be viewed as a local factor which could contribute to the progressive narrowing of the IAC diameter. The onset was brutal and apparently triggered during scuba diving, in the ascending phase, during which gases diffuse largely into the sinuses, middle ear cavities, and the petrosal air cell system, in a VM-accelerated manner. Although VM is commonly used in diving to equalize gas

pressure between middle ear, mastoid air cell system, and the rhino pharynx via the Eustachian tube, this maneuver transiently increases intracranial pressure (ICP) ^[9]. Thus, an already narrowed IAC stretching the right CVN associated to a transient ICP elevation—stimulated by VM—would generate a supplementary mechanical constraint on the nerve, triggering persistent audio-vestibular symptoms.

The term vestibular paroxysmia (VP) ^[10] was introduced by Brandt et al. ^[11] to describe brief and intense vertigo and tinnitus generated by dysfunction of the CVN, a compression induced by a vessel in the cerebellopontine angle. Diagnostic criteria were recently proposed by the International Classification of Vestibular Disorders ^[5]. Although MRI was not evocative in this case of a “classic” neuro-vascular compression, right IAC appeared narrowed and stretched by hyperpneumatization. However, the criteria for the diagnosis of VP were fulfilled despite an apparently slightly different mechanism, and as proposed in neural compression by a blood vessel ^[12] a trial with a neuronal membrane stabilizer (oxcarbazepine) was proposed with substantial improvement consistent with the onset of drug use.

CONCLUSION

In patients with extensive HPTB and narrowed IAC, complaining of recurrent spinning vertigos, dizziness, tinnitus, and similar signs evocative of VP, the potential risk-to-benefit ratio of a low-dose oxcarbazepine should be discussed. To the best of our knowledge, this is the first case report of a patient which complained of vestibular signs that may be correlated with a compression of CVN in the context of a narrowed IAC associated to an extensive HPTB.

REFERENCES

1. Han SJ, Song MH, Kim J, Lee WS, Lee HK. Classification of temporal bone pneumatization based on sigmoid sinus using computed tomography. *Clin Radiol* 2007; 62: 1110-8. [\[Crossref\]](#)
2. Virapongse C, Sarwar M, Bhimani S, Sasaki C, Shapiro R. Computed tomography of temporal bone pneumatization: normal pattern and morphology. *AJR Am J Roentgenol* 1985; 145: 473-81. [\[Crossref\]](#)
3. Califano L, Mellilo MG, Vassallo A, Mazonne S. Hyperventilation-induced nystagmus in a large series of vestibular patients. *Acta Otorhinolaryngologica Italica* 2011; 31: 17-26.
4. Marques SR, Ajzen SD, Ippolito G, Alonso L, Isotani S, Lederman H. Morphometric analysis of the internal auditory canal by computed tomography imaging. *Iran J Radiol* 2012; 9: 71-8. [\[Crossref\]](#)
5. Strupp M, Lopez-Escamez JA, Kim JS, Straumann D, Jen J, Carey J, et al. Vestibular paroxysmia: Diagnostic criteria Consensus document of the Committee for the Classification of Vestibular Disorders of the Bárány Society. (<http://www.jvr-web.org/ICVD.html>). *J Vestib Res* 2016; 26: 409-15. [\[Crossref\]](#)
6. Vattoth S, Shah R, Curé JK. A compartment-based approach for the imaging evaluation of tinnitus. *Am J Neuroradiol* 2010; 31: 211-8. [\[Crossref\]](#)
7. Tüz M, Dofru H, Yeoldaf A. Subjective pulsatile tinnitus associated with extensive pneumatization of temporal bone. *Auris Nasus Larynx* 2003; 30: 183-5. [\[Crossref\]](#)
8. Klingmann C, Knauth M, Plinkert PK. Alternobaric vertigo - really a hazard? *Otol Neurotol* 2006; 27: 1120-5. [\[Crossref\]](#)
9. Jellinek EH. The Valsalva manoeuvre and Antonio Valsalva (1666-1723). *J R Soc Med* 2006; 99: 448-51. [\[Crossref\]](#)
10. Jannetta PJ. Neurovascular cross-compression in patients with hyperactive dysfunction symptoms of the eighth cranial nerve. *Surg Forum* 1975; 26: 467-9.
11. Brandt T, Strupp M, Dieterich M. Vestibular paroxysmia: a treatable neurovascular cross-compression syndrome. *J Neurol* 2016; 263: 0-6. [\[Crossref\]](#)
12. Russell D, Baloh RW. Gabapentin responsive audiovestibular paroxysmia. *J Neurol Sci* 2009; 281: 99-100. [\[Crossref\]](#)