

## Case Report

# Capillary Venous Malformation With Secondary Aneurysmal Bone Cyst of Temporal Bone

Federica Canzano<sup>1</sup> , Ermanno Giombelli<sup>2</sup> , Davide Cerasti<sup>2</sup> , Domenico Corradi<sup>3</sup> ,  
Maurizio Falcioni<sup>1</sup> 

<sup>1</sup>Department of Head and Neck – Otolaryngology and Neurotology, University Hospital of Parma, Parma, Italy

<sup>2</sup>Neurosurgery Department, University Hospital of Parma, via Gramsci, Parma, Italy

<sup>3</sup>Neuroradiology Unit, Radiology Department, University Hospital of Parma, via Gramsci, Parma, Italy

ORCID IDs of the authors: F.C. 0000-0002-6876-8185; E.G. 0000-0002-8459-6678; D.C. 0000-0002-3654-4830; D.C. 0000-0002-8836-4778; M.F. 0000-0003-2455-8298

Cite this article as: Canzano F, Giombelli E, Cerasti D, Corradi D, Falcioni M. Capillary venous malformation with secondary aneurysmal bone cyst of temporal bone. *J Int Adv Otol*. 2021; 17(5): 471-474.

Aneurysmal bone cysts (ABCs) arising from vascular malformation are extremely rare, and none have been reported in the literature in English till now. We report a very rare case of secondary ABC of left temporal bone in a 5-year-old Caucasian boy who presented with a left sudden facial palsy associated with a painless non-tender mass of the left temporo-parietal region. The computed tomography (CT) and magnetic resonance imaging (MRI) features were suggestive of ABC secondary to a capillary venous malformation, with concurrent involvement of the squamous, mastoid, and petrous portions of the temporal bone. Surgical resection was performed. On follow-up, the patient was found to be doing well.

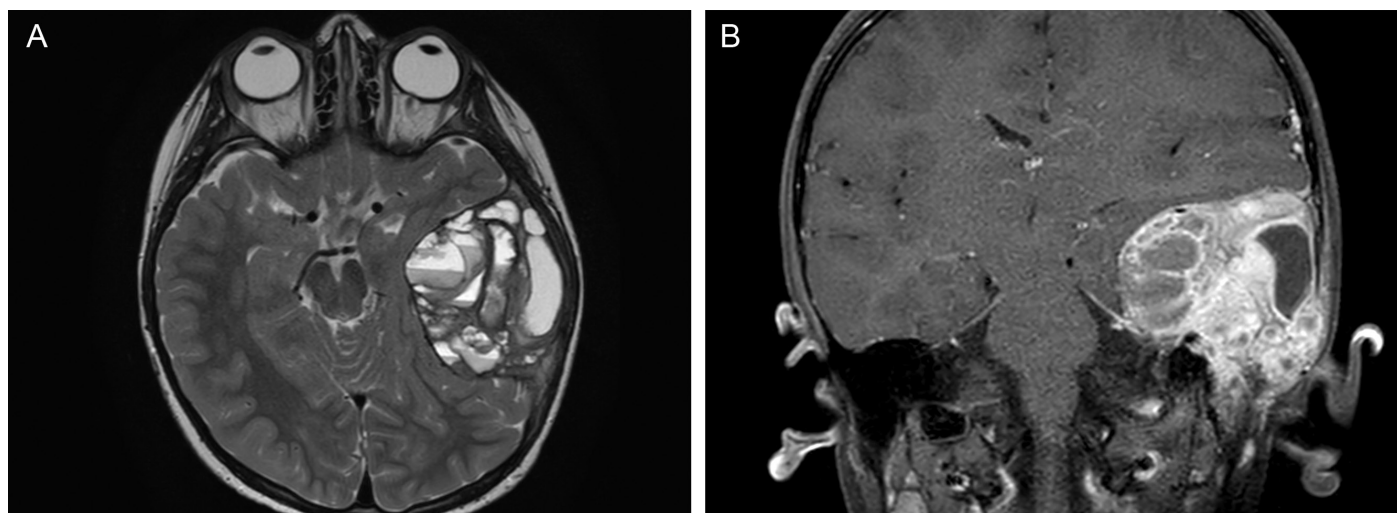
**KEYWORDS:** Aneurysmal bone cyst, capillary venous malformation, temporal bone, subtotal petrosectomy, facial nerve

## INTRODUCTION

Aneurysmal bone cysts (ABCs) arising from vascular malformation are extremely rare, and till now no craniofacial ABC secondary to capillary vascular malformations (CVMs) have been reported in the literature in English. We report a very rare case of secondary ABC of left temporal bone in a 5-year-old Caucasian boy who presented with a left sudden facial palsy associated with a painless non-tender mass of the left temporo-parietal region. The computed tomography (CT) and magnetic resonance imaging (MRI) features were suggestive of ABC secondary to a capillary venous malformation, with concurrent involvement of the squamous, mastoid, and petrous portions of the temporal bone. Surgical resection was performed. On follow-up, the patient was doing well.

## CASE PRESENTATION

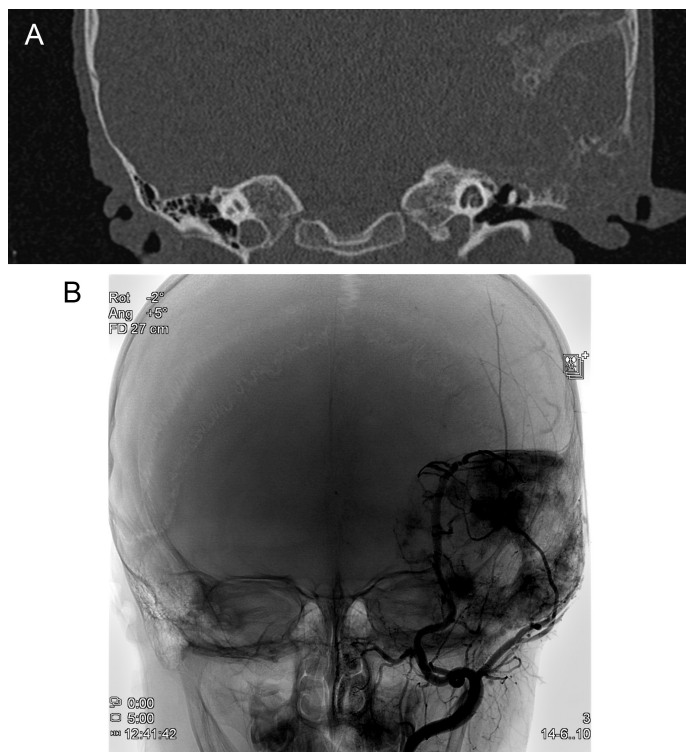
A 5-year-old boy presented to our center with a sudden left facial palsy; his parents denied any history of trauma or other associated symptoms. The facial nerve (FN) function improved from grade 6 to grade 3 after the administration of corticosteroids. On local examination, there was a painless non-tender mass in the left temporo-parietal region; otoscopy was normal bilaterally. Audiometry revealed a mild conductive hearing loss in the left ear. A fundoscopic examination showed papilledema and little hemorrhage around the left optic disc. MRI detected an encapsulated, large, expansile, extra-dural, multi-cystic lesion in the petrous and squamous temporal bones. The lesion compressed the temporal lobe extradurally. The cystic portion of the mass had fluid-fluid levels, low signal intensity on T1 (Figure 1A) weighted images, and high signal intensity on T2 weighted images (Figure 1B). A thin rim of low signal intensity surrounded the lesion, with non-homogeneous contrast enhancement. No flow mass was visible in the sigmoid sinus and the jugular bulb. The CT scan revealed an erosion of the inner and outer tables of the skull, and a large area of erosion of the presigmoid posterior fossa dura plate (Figure 1A and B). There was a significant mastoid involvement, with complete erosion of the left tegmen tympani and a partial erosion of bony external auditory canal (Figure 2A). The tympanic cavity was occupied by hypodense pathological tissue. The bony destruction surrounded the posterior labyrinth with initial erosion of superior and posterior semicircular canals. The lesion had vascular features. As a consequence, the patient underwent a digital angiography that confirmed different components inside the lesion, some of them with intensive blush and others with no signal at all (Figure 2B).



**Figure 1.** (A) Pre-operative MR images (axial T2 sequence): multiloculated osseous lesion with multiple fluid-fluid levels. (B) Pre-operative MR images (coronal post-contrast-enhancement T1WI sequence): a thin rim of low signal intensity surrounded the lesion with non-homogeneous contrast enhancement.

The lesion was embolized with polyvinyl alcohol particles (PVA 250-355 microns) and 3 hypertrophic feeding arteries (middle meningeal, ascending pharyngeal, and superficial temporal) were closed with coils. Surgical removal was planned by an otological-neurosurgical team through a temporal-parietal craniotomy with subtotal petrosectomy. The FN was identified at the mastoid portion and followed to the geniculate ganglion, where it was compressed by the lesion. This latter was multicystic and had a well-formed

capsule adherent to the dura. However, it was possible to establish and follow a cleavage plane with the dura of both the middle and the posterior cranial fossa. In spite of severe bleeding, gross total removal was achieved, with anatomical preservation of the inner ear. At the end of the procedure, the temporal bone cavity was obliterated by abdominal fat and a cranioplasty was performed using a titanium mesh. In spite of the pre-operative embolization, severe intraoperative blood loss occurred (hemoglobin 6 g/dL), requiring 3 units of red blood cells.



**Figure 2.** (A) Pre-operative CT (coronal) with erosion of the inner and outer table of the skull, a complete erosion of the left tegmen tympani, and a partial erosion of bony external auditory canal. (B) Pre-embolization digital subtraction angiography: global left external injection shows the mass, which is mainly fed by the middle meningeal artery, ascending pharyngeal artery, and superficial temporal artery; it also shows areas with intensive blush and others with no signal at all.

Histological examination revealed cystic spaces filled with blood divided by fibrous septa consisting of immature bone trabeculae, giant cells, hemosiderin-filled macrophages, and fibroblasts. Multilocular cavernous spaces of different dimensions were observed, delineated by fine membranous septa composed of fibrous tissue with thin-walled capillaries and inflammatory cells. The findings were consistent with the diagnosis of CVM with secondary ABC (Figure 3).

Post-operative FN function remained grade 3; pure-tone audiometry revealed a conductive hearing loss with the deterioration of the bone conduction limited to the 4000 and 8000 Hz frequencies.

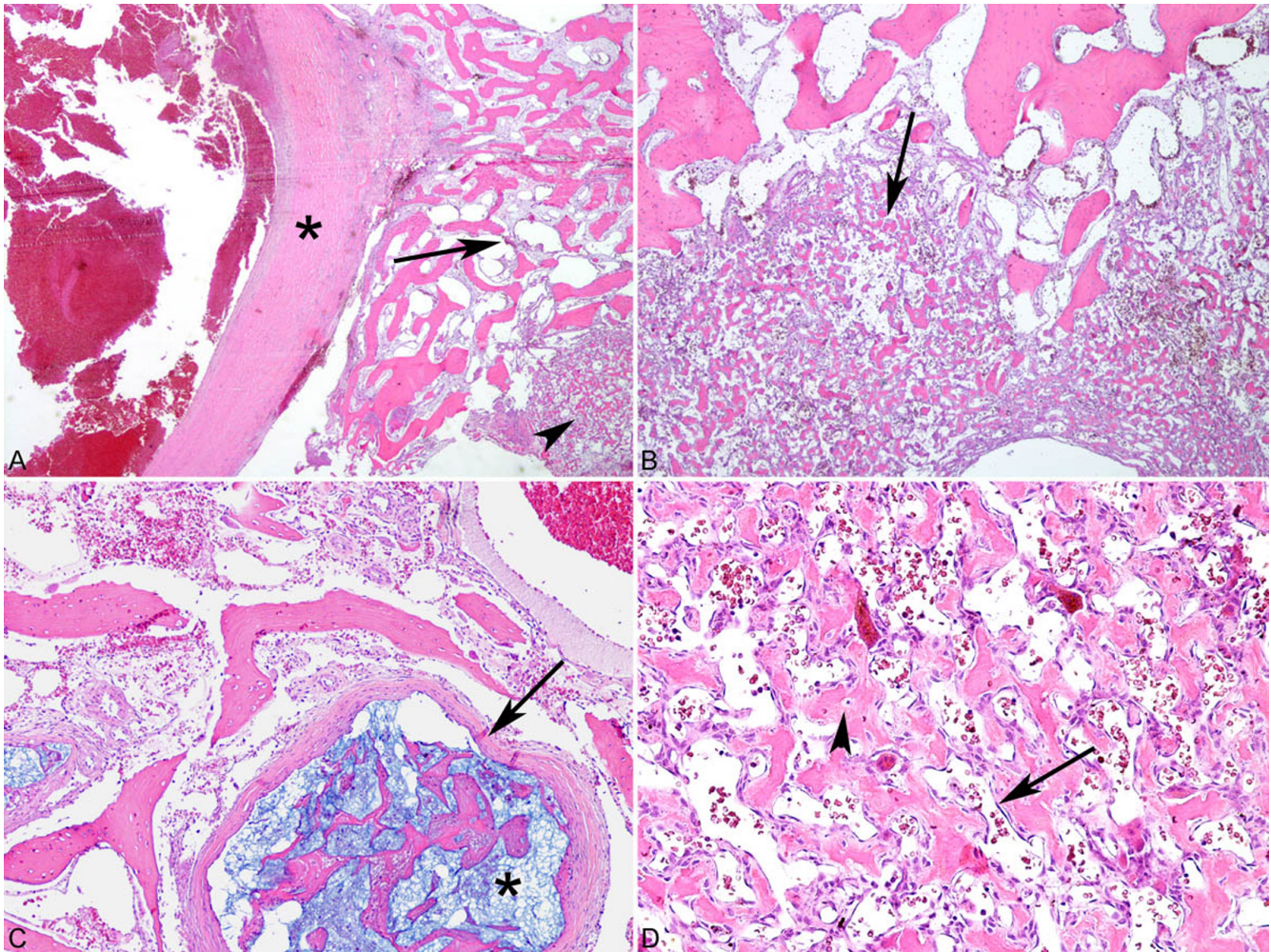
At 6 months, the FN function had recovered to grade I. Postoperative MRI (Figure 4) 2 years later confirmed the gross total resection of the tumor as well as the re-expansion of the temporal lobe.

## DISCUSSION

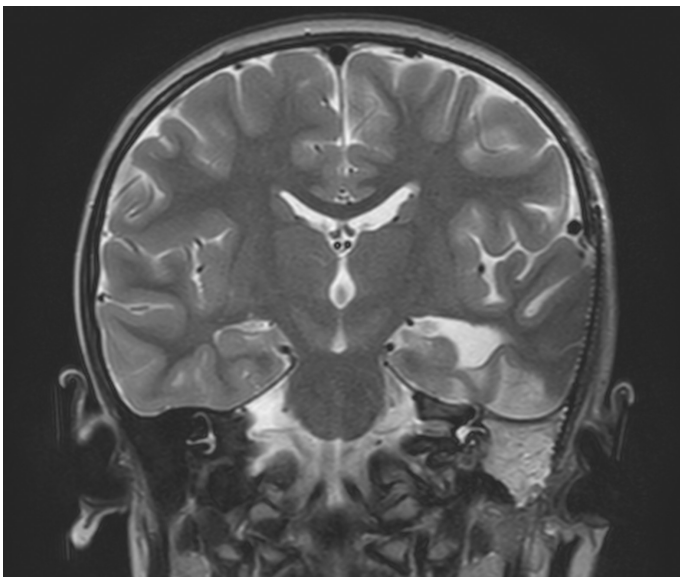
CVMs are low-flow vascular malformations that consist of dysplastic endothelial-lined venous channels. They are present at birth, but the age of presentation depends on size and location. These lesions do not regress spontaneously and grow proportionately with the child and may enlarge during puberty.<sup>1</sup>

On CT, these lesions can appear as a honeycomb expansive mass with non-infiltrating aspect. On MRI, CVMs are isointense on T1 and hyperintense on T2-weighted imaging. Generally, phleboliths and vascular lakes are highly suggestive of a CVM lesion.<sup>2</sup> CVMs involving temporal bone have never been reported in the literature in English.





**Figure 3.** Histopathology: original magnification (A) 2×; (B) 4×; (C) 10× and (D) 20×. Staining (A-D) hematoxylin-eosin. (A) The bone (arrow) is largely replaced by a small-vessel benign proliferation (arrowhead). In addition, large cavernous non-specific vessels (asterisk) can be detected in some areas. (B) The small-vessel proliferation (arrow) forms significant areas replacing, and focally infiltrating, the bone, which shows reactive changes. (C) There are sparse and dilated venous channels (arrow) with signs of iatrogenic pre-operative embolization (asterisk). (D) The small-vessel benign proliferation consists of thin dilated channels (arrow) with foci of osteoid matrix (arrowhead).



**Figure 4.** Post-operative MRI control shows complete excision of the mass (C coronal T2WI) re-expansion of the temporal lobe.

An ABC is a benign, non-neoplastic, expansile osseous lesion occurring mainly in females, and represents only 1% to 2% of all primary bone tumors. Between 3% and 12% of ABCs occur in the head and neck, with common locations being the maxilla, orbit, ethmoid, and frontal bones.<sup>3</sup> On imaging, they appear as expansile masses with multiple cystic spaces, characterized by hemorrhage with large, blood-filled cavities and fluid-fluid levels. ABCs are occasionally found in the temporal bone. In the literature, 42 cases of ABC involving the temporal bone have been reported.<sup>4-6</sup>

Temporal bone involvement by ABC is usually limited to the squamous portion. Only 6 cases of ABC involving the petrous and/or mastoid portion of the temporal bone have been reported in the literature.<sup>6</sup>

ABCs can be secondary to several bone lesions such as chondroblastoma, fibrous dysplasia<sup>7</sup> chondroblastoma, osteoblastoma, eosinophilic granuloma, or hemangioma.<sup>8</sup> ABCs arising from vascular malformation are extremely rare, and till now, no craniofacial ABCs secondary to CVM have been reported in the literature in English.

The different components of the lesion can be detected radiologically, as in our case. In fact, the lesion showed lakes with fluid collection (ABC) intermixed with areas of massive vascularization (CVM). The same characteristics were confirmed during the surgery. The ABC components were easily removed after evacuation of the fluid content, while the severe bleeding from the CVM was difficult to control throughout the surgery.

In spite of pre-operative embolization, severe bleeding was the most important technical problem during surgery, due to CVM. In fact, ABCs are not vascularized lesions and rarely require embolization.<sup>4,9</sup>

## CONCLUSION

To our knowledge, this is the first report of ABC secondary to a capillary venous malformation with concurrent involvement of the squamous, mastoid, and petrous portions of the temporal bone.

**Informed Consent:** Written informed consent was obtained from patient's parents.

**Peer-review:** Externally peer-reviewed.

**Author Contributions:** Concept – M.F.; Design – M.F.; Supervision – M.F.; Resource – F.C., M.F.; Materials – D.C., E.G., D.C.; Data Collection and/or Processing – F.C.; M.F.; Analysis and/or Interpretation – F.C., M.F.; Literature Search – F.C.; Writing – F.C., M.F.; Critical Reviews – M.F.

**Conflict of Interest:** The authors have no conflict of interest to declare.

**Financial Disclosure:** The authors declared that this study has received no financial support.

## REFERENCES

1. Mulliken JB, Fishman SJ, Burrows PE. Vascular anomalies. *Curr Probl Surg*. 2000;37(8):517-584. [\[CrossRef\]](#)
2. Steinklein JM, Shatzkes DR. Imaging of vascular lesions of the head and neck. *Otolaryngol Clin North Am*. 2018;51(1):55-76. [\[CrossRef\]](#)
3. Citardi MJ, Janjua T, Abrahams JJ, Sasaki CT. Orbitoethmoid aneurysmal bone cyst. *Otolaryngol Head Neck Surg*. 1996;114(3):466-470. [\[CrossRef\]](#)
4. Kim BJ, Lee EJ, Chang HW, et al. Aneurysmal bone cyst in the temporal bone and complete resection with preoperative embolization. A case report. *Interv Neuroradiol*. 2014;20(5):609-613. [\[CrossRef\]](#)
5. Kletke SN, Popovic S, Algirdur A. Aneurysmal bone cyst of the temporal bone presenting with headache and partial facial palsy. *J Neurol Surg Rep*. 2015;76: e18-e22. [\[CrossRef\]](#)
6. Sharma M, Velho V, Kharosekar H. Primary aneurysmal bone cyst of the petrous temporal bone: A case report and review of literature. *Asian J Neurosurg*. 2016;11(4):444. [\[CrossRef\]](#)
7. Haddad GF, Hambali F, Mufarrij A, Nassar A, Haddad FS. Concomitant fibrous dysplasia and aneurysmal bone cyst of the skull base. Case report and review of the literature. *Pediatr Neurosurg*. 1998;28(3):147-153. [\[CrossRef\]](#)
8. Mendenhall WM, Zlotecki RA, Gibbs CP, et al. Aneurysmal bone cyst. *Am J Clin Oncol*. 2006;29(3):311-315. [\[CrossRef\]](#)
9. Sayama CM, MacDonald JD. Aneurysmal bone cyst of the petrous bone: case presentation and review of the literature. *Pediatr Neurosurg*. 2010;46(4):308-312. [\[CrossRef\]](#)