

Original Article

# Localization of the Vertical Part of the Facial Nerve in the High-Resolution Computed Tomography During Pediatric Cochlear Implantation

Mahmoud Mandour<sup>1</sup>, Mohamed Amer<sup>1</sup>, Saad Elzayat<sup>2</sup>, Edoardo Covelli<sup>3</sup>,  
Maurizio Barbara<sup>3</sup>, Rasha Lotfy<sup>4</sup>, Haitham H. Elfarargy<sup>2</sup>, Mohamed Osama Tomoum<sup>1</sup>

<sup>1</sup>Department of Otorhinolaryngology, Tanta University, Faculty of Medicine, Tanta, Egypt

<sup>2</sup>Department of Otorhinolaryngology, Kafrelsheikh University, Faculty of Medicine, Kafrelsheikh, Egypt

<sup>3</sup>Department of Neuroscience, Mental Health and Sensory Organs, Sant' Andrea University Hospital, Sapienza University, Faculty of Medicine and Psychology, Rome, Italy

<sup>4</sup>Department of Radiology, Tanta University, Faculty of Medicine, Tanta, Egypt

ORCID IDs of the authors: M.M. 0000-0002-2643-6502, M.A. 0000-0002-0478-8689, S.E. 0000-0002-9477-2460, E.C. 0000-0003-0863-5943, M.B. 0000-0003-0740-0384, R.L. 0000-0002-7579-8681, H.H.E. 0000-0001-5303-2012, M.O.T. 0000-0003-0701-9444.

Cite this article as: Mandour M, Amer M, Elzayat S, et al. Localization of the vertical part of the facial nerve in the high-resolution computed tomography during pediatric cochlear implantation. *J Int Adv Otol.* 2024;20(1):8-13.

**BACKGROUND:** This study proposed a classification of the vertical portion of the facial nerve (VPFN) location, incorporating the previous classifications regarding the posterior-to-anterior and medial-to-lateral dimensions. We also evaluated the implication of this proposed classification on the round window visibility during pediatric cochlear implantation (CI).

**METHODS:** It was a retrospective multicenter observational cohort study. This study included 334 cases that underwent CI between 2015 and 2022 at multiple referral institutes. Two physicians evaluated the preoperative computed tomography images of 334 patients and determined the radiological type of the VPFN. These types were matched with intraoperative round window accessibility.

**RESULTS:** The Spearman's correlation coefficient showed a strong correlation between the proposed VPFN type and the intraoperative round window visibility, as the *P*-value was <.001.

**CONCLUSION:** This classification could provide the surgeon preoperatively with the precise location of the VPFN in the lateral-to-medial and posterior-to-anterior dimensions. Furthermore, this location classification of the VPFN was significantly correlated with intraoperative round window accessibility, with an accuracy of 90.42%. Therefore, types C and D were expected to have difficult accessibility into the round window, and more surgical interventions were needed to modify the posterior tympanotomy or use other approaches.

**KEYWORDS:** Cochlear implantation, computed tomography, facial nerve, round window, radiological localization, surgical approaches

## INTRODUCTION

Cochlear implantation (CI) is the standard surgical solution for severely deaf patients. Although CI is a relatively safe procedure with a low rate of severe sequelae (2.3%), it still has the possibility of complications. Among them, iatrogenic facial nerve (FN) paralysis is a significant surgical issue which may occur in 0.67%-1.2% of CI surgeries.<sup>1</sup> The facial recess (FR) route, with electrode arrays inserted into the scala tympani after a posterior tympanotomy (PT), is determined as the standard approach of CI.<sup>2</sup> Maximum visibility of the round window (RW) through a PT is the primary step for effective electrode insertion. The boundaries of the triangular FR are the vertical portion of the facial nerve (VPFN) posteromedially, the chorda tympani nerve anterolaterally, and the fossa incudis and the incus buttress superiorly.<sup>3</sup>

The course of the VPFN may be aberrated in several ways. For example, it can be anterior displaced, lateral displaced, or bifurcated. This aberration may impact the RW accessibility through the traditional posterior tympanotomy.<sup>4</sup> Furthermore, in extreme

Corresponding author: Haitham H. Elfarargy, e-mail: Hitham\_elfarargy@med.kfs.edu.eg

Received: May 16, 2023 • Revision requested: July 15, 2023 • Last revision received: July 28, 2023 •

Accepted: September 2, 2023 • Publication Date: January 31, 2024

Available online at [www.advancedotology.org](http://www.advancedotology.org)



Content of this journal is licensed under a  
Creative Commons Attribution-NonCommercial  
4.0 International License.

abnormalities, RW may be completely inaccessible. Therefore, other approaches, such as the retrofacial approach, may be used in these cases.<sup>5</sup>

Each surgeon tries to evaluate the high-resolution computed tomography (HRCT) to delineate the VPFN course and detect any associated aberrations that may restrict access to the RW and impede electrode insertion.<sup>6</sup> Also, as we are dealing with a bony FR area, the HRCT may provide the surgeon with sufficient details in the preoperative evaluation, preparing him for possible intraoperative difficulties.<sup>7</sup>

Many previous radiological studies tried to evaluate the VPFN course related to CI. For example, Telmesani et al attempted to assess the course of the VPFN in the medial-to-lateral dimension only with the possibility of lateral displacement of the VPFN.<sup>8</sup> On the other side, Mandour et al assessed the course of the VPFN in the posterior-to-anterior dimension only with the possibility of the anterior displacement of the VPFN.<sup>9</sup>

This study aimed to combine the previous radiological trials and determine the accurate location of the VPFN. We proposed a radiological classification of the VPFN location in posterior-to-anterior and medial-to-lateral dimensions, incorporating the earlier classifications of Telmesani et al and Mandour et al. We also evaluated the effect of this classification on intraoperative RW visibility during pediatric CI.

## MATERIAL AND METHODS

This retrospective observational study included patients who underwent CI surgery from 2015 to 2022. This research was approved by the ethical committee of Tanta University (Approval no: 35731/9/22). Also, it followed the instructions of the Declaration of Helsinki. Furthermore, the patients' parents signed informed consent to share their data in our study.

Through the national CI program, we included pediatric cases (up to 12-years-old) who underwent CI surgery because of bilateral profound hearing loss. We had only those with the preoperative CT scan images and the unedited surgical videos. We excluded cases with previous ear operations, cholesteatoma, secretory otitis media, congenital cochleovestibular anomalies, facial nerve paralysis, and external auditory canal (EAC) anomalies. So out of 478 patients, we included 334 patients.

### MAIN POINTS

- This study proposed a classification of the vertical portion of the facial nerve (VPFN) location, incorporating the previous classifications regarding the posterior-to-anterior and medial-to-lateral dimensions.
- The Spearman's correlation coefficient showed a strong correlation between the proposed VPFN type and the intraoperative RW visibility.
- Types C and D were expected to have difficult accessibility into the RW, and more surgical interventions were needed to modify the posterior tympanotomy or use other approaches.

## Computed Tomography Coronal Plane Reconstruction Maneuver

The 0.6 mm raw images were put on the console viewer in 3 orthogonal axes: axial, coronal, and sagittal. The sagittal cut was played until the view of the lateral semicircular canal (LSC) was represented by the 2 points of the anterior and posterior limbs; the axial cut was considered by connecting the dots. Coronal cuts were established in a plane perpendicular to axial images at 0.6-0.5 mm intervals.

## Computed Tomography Reviewing

Two physicians evaluated the coronal images of the HRCT scan independently. First, coronal cuts were assessed in succession from posterior to anterior until VPFN was detected. Then, it was followed by the subsequent coronal cuts until it was no longer seen. Finally, the final coronal image of the identified VPFN, superior to the stylomastoid foramen, was chosen to decide the site of the VPFN in the posterior-to-anterior and medial-to-lateral dimensions of the LSC.

According to this association, we suggested a radiological categorization that may determine the localization of the VPFN (Figure 1):

**Type A:** The VPFN is posterior to the LSC's anterior limb and medial to or at the same level as the LSC's most lateral portion (Figure 2).

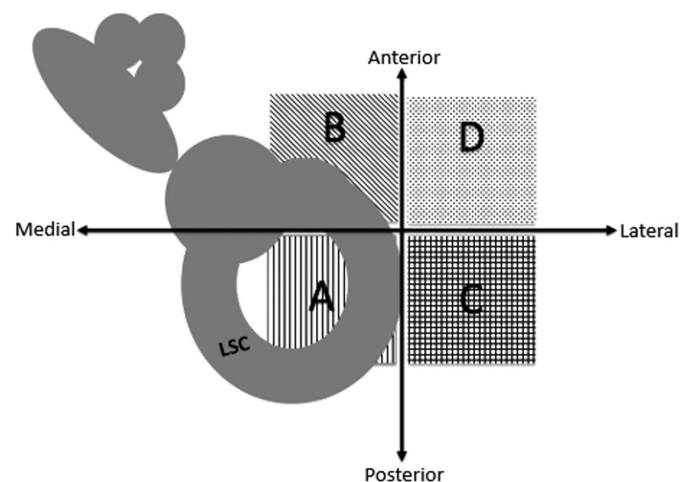
**Type B:** The VPFN is anterior to or at the same extent as the LSC's anterior portion and medial to or at the same level as the LSC's most lateral portion (Figure 3).

**Type C:** The VPFN is posterior to the LSC's anterior limb and lateral to the LSC's most lateral portion (Figure 4).

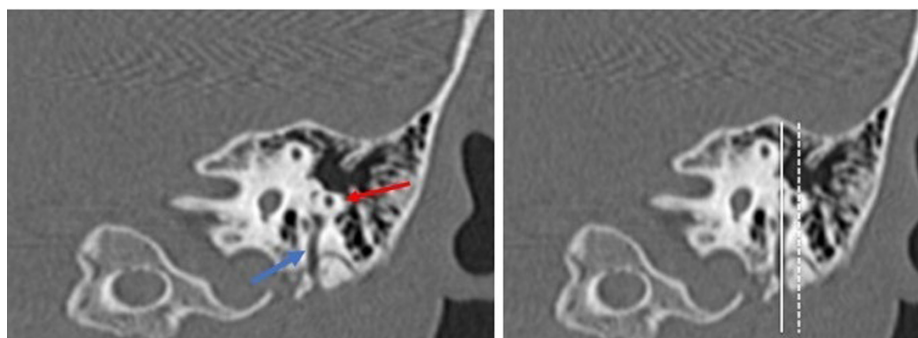
**Type D:** The VPFN is anterior to or at the same extent as the LSC's anterior portion and lateral to the LSC's most lateral portion (Figure 5).

## Surgical Videos Reviewing

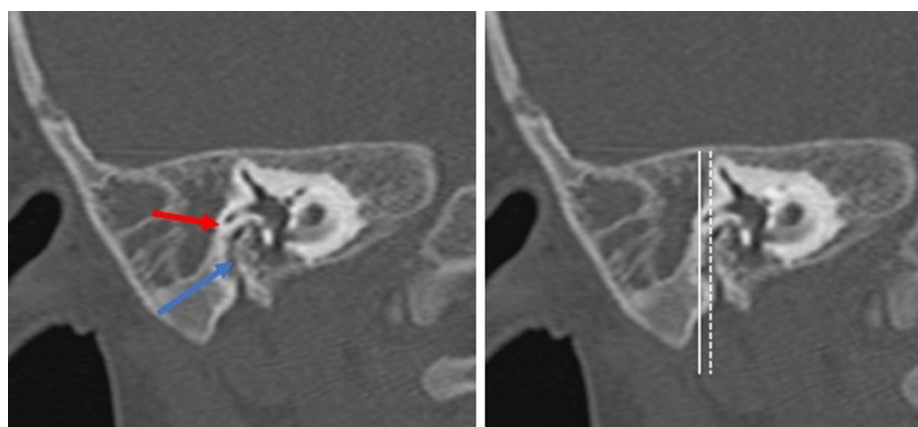
Two senior CI surgeons (other than the HRCT reviewers), blind to the previously mentioned radiological type of the VPFN, independently reviewed each case's surgical video. Each one determined if the accessibility to the RW and electrode insertion was done through the classical PT or if extrasurgical interventions were needed to access the RW. These surgical interventions included: more thinning of the



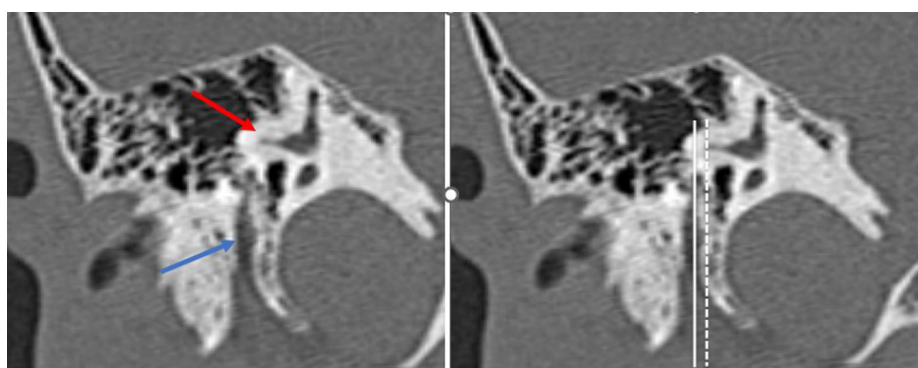
**Figure 1.** A graphic showing the 4 types of vertical portion of the facial nerve about the lateral semicircular canal.



**Figure 2.** A left coronal image of the high-resolution computed tomography shows type A VPFN (the blue arrow is the VPFN; the red arrow is the LSC; the white line passes tangentially to the VPFN; the dashed line passes tangentially to the LSC). LSC, lateral semicircular canal; VPFN, vertical portion of the facial nerve.



**Figure 3.** A right coronal image of the high-resolution computed tomography shows type B VPFN (the blue arrow is the VPFN; the red arrow: the LSC is the white line passes tangentially to the VPFN; the dashed line passes tangentially to the LSC). LSC, lateral semicircular canal; VPFN, vertical portion of the facial nerve.



**Figure 4.** A right coronal image of the high-resolution computed tomography shows type C VPFN (the blue arrow is the VPFN; the red arrow is the LSC; the white line passes tangentially to the VPFN; the dashed line passes tangentially to the LSC). LSC, lateral semicircular canal; VPFN, vertical portion of the facial nerve.

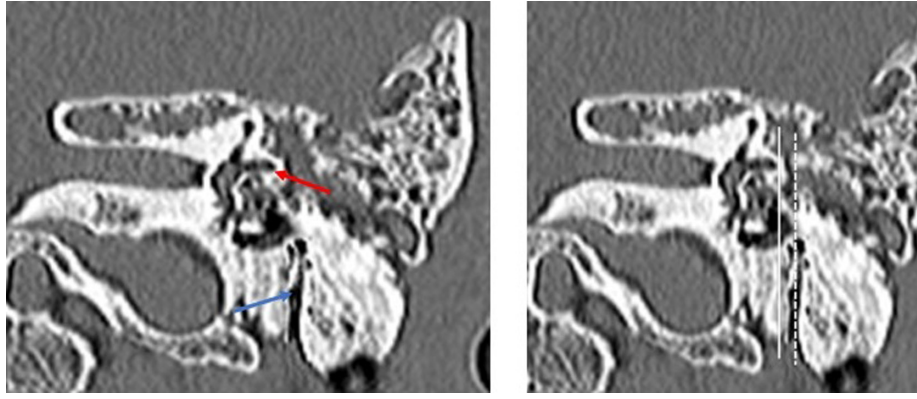
posterior wall of the EAC (with or without anterior fine fracture), uncapping of the VPFN, cutting the chorda tympani nerve, drilling the incus buttress, the elevation of the tympanomeatal flap with the use of otoendoscopy, and using another approach. Round window accessibility entailed good visibility of RW and possible manipulation of the surgical instruments simultaneously.

#### Outcomes Measures

We matched the preoperative localization of the VPFN with the RW visibility. We also evaluated the power of this categorization to anticipate RW visibility preoperatively and determine if extrasurgical interventions may be needed to achieve this accessibility.

#### Statistical Analysis

We used the Kruskal–Wallis analysis to compare the 4 groups of the VPFN (significance was present if  $P < .05$ ). Next, matching the preoperative localization of the VPFN with intraoperative RW accessibility was done using the Spearman correlation coefficient (significance was present if  $P < .01$ ). Next, the chi-square test compared the RW accessibility of each group (significance was present if  $P < .05$ ). Finally, the intraclass correlation coefficient was used to evaluate the interobserver variability ( $>0.7$  meant good agreement). This analysis was performed by the Statistical Package for the Social Sciences Statistics, version 28.0 (IBM SPSS Corp.; Armonk, NY, USA). The sensitivity, specificity, and accuracy were calculated using MedCalc© 2023 Software Ltd.



**Figure 5.** A left coronal cut of the High-resolution computed tomography shows type D VPFN (the blue arrow is the VPFN; the red arrow is the LSC; the white line passes tangentially to the VPFN; the dashed line passes tangentially to the LSC). LSC, lateral semicircular canal; VPFN, vertical portion of the facial nerve.

## RESULTS

The patients were grouped into 4 groups according to the pre-operative radiological type of the VPFN. The first group included 186 patients (56%) with type A VPFN. The second group included 78 patients (23%) with type B VPFN. The third group had 51 cases (15%) with type C VPFN. The last group included 19 cases (6%) with type D VPFN. The intraclass correlation coefficient between both preoperative CT reviewers, reflecting the interobserver variability, was 0.98, which indicated a good agreement between them.

The 4 groups did not differ statistically regarding age, sex, and the surgery side, as the *P*-values were greater than 0.05 (Table 1).

Three patients (2%) in group A, 15 (19%) patients in group B, 37 (72%) in group C, and all patients of group D required extrasurgical

interventions to access the RW and insert the electrode. The 4 groups differed statistically regarding the need for more surgical interventions to access the RW, as the *P*-value was <.001. The intraclass correlation coefficient between surgical video reviewers was 0.99, indicating excellent agreement (Table 1, Figure 6).

The Spearman's correlation coefficient revealed a strong correlation between the radiological VPFN type and the intraoperative RW visibility, as the *P*-value was <.001. In contrast, there was an insignificant correlation of RW accessibility with age (*P* = .165), sex (*P* = .361), or the operation side (*P* = .334).

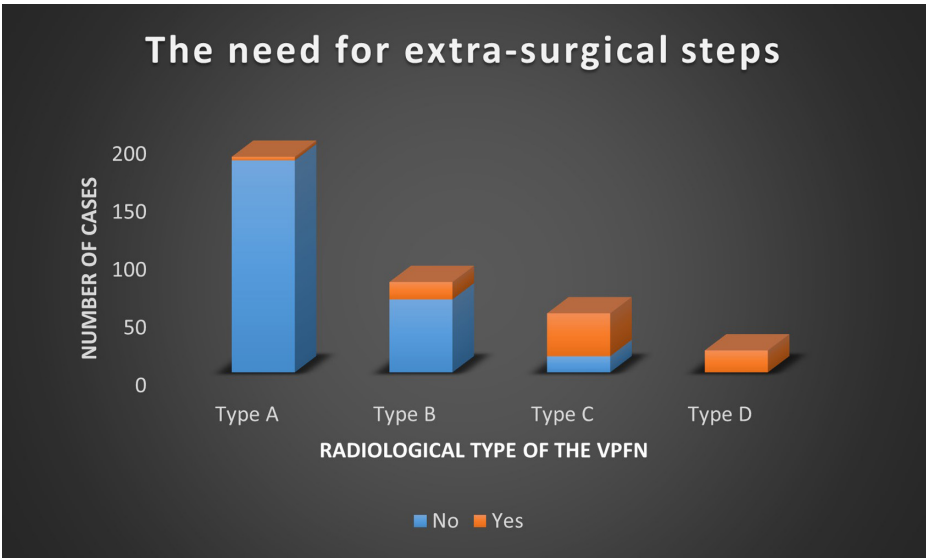
Moreover, this proposed radiological localization of the VPFN had an accuracy of 90.42%, a sensitivity of 75.68%, and a specificity of 94.62% to predict the accessibility to the RW preoperatively and if it may need extrasurgical interventions (Table 2).

**Table 1.** Results of the 4 Types of VPFN

		Type A N = 186 (56%)	Type B N = 78 (23%)	Type C N = 51 (15%)	Type D N = 19 (6%)	<i>P</i>
Age (years)	Minimum	2	2.1	1.9	2	.19
	Maximum	8.3	8	7.9	6.4	
	Mean $\pm$ SD	4.92 $\pm$ 1.21	5.13 $\pm$ 1.15	4.6 $\pm$ 1.53	4.72 $\pm$ 1.4	
Sex	Male	115/186 (61.8%)	44/78 (56.4%)	29/51 (56.9%)	8/19 (42.1%)	.37
	Female	71/186 (38.2%)	34/78 (43.6%)	22/51 (43.1%)	11/19 (57.9%)	
Side	Right	159/186 (85.5%)	66/78 (84.6%)	47/51 (92.2%)	13/19 (68.4%)	.1
	Left	27/186 (14.5%)	12/78 (15.4%)	4/51 (7.8%)	6/19 (31.6%)	
Need for extrasurgical interventions	No	183/186 (98.4%)	63/78 (80.8%)	14/51 (27.5%)	0	<.001*
	Yes	3/186 (1.6%)	15/78 (19.2%)	37/51 (72.5%)	19/19 (100%)	
	<i>P</i> (of each type)	<.001*	<.001*	<.001*	<.001*	
Extrasurgical interventions	No	183/186 (98.4%)	63/78 (80.8%)	14/51 (27.5%)	0	<.001*
	Thinning of EAC wall	3/186 (1.61%)	8/78 (10.25%)	0	0	
	Uncapping of VPFN	0	5/78 (6.4%)	8/51 (15.7%)	0	
	Sacrificing CTN	0	0	4/51 (7.8%)	0	
	Removal of buttress incus	0	1/78 (1.3%)	7/51 (13.7%)	5/19 (26.3%)	
	Use of the endoscope	0	1/78 (1.3%)	18 (35.3%)	12/19 (63.2%)	
	Retrofacial approach	0	0	0	2/19 (10.5%)	

CTN, chorda tympani nerve; EAC, external auditory canal; VPFN, vertical portion of the facial nerve. \*Significant as *P* < .05.





**Figure 6.** A bar chart shows the need for extrasurgical interventions of each type of vertical portion of the facial nerve to access the round window.

**Table 2.** Assessment of the Classification of the VPFFN Capability to Predict Round Window Accessibility

Statistic	Value	95% CI
Sensitivity	75.68%	64.31-84.9
Specificity	94.62%	91.13-97.03
Positive likelihood ratio	14.05	8.31-23.77
Negative likelihood ratio	0.26	0.17-0.38
Positive predictive value	80%	70.28-87.12
Negative predictive value	93.18%	90.13-95.34
Accuracy	90.42%	86.74-93.35

CI, confidence interval; VPFFN, vertical portion of the facial nerve.

DISCUSSION

Localization of the VPFFN is one of the cornerstones of the preoperative radiological evaluation of CI surgery. VPFFN constitutes 1 of the 3 borders of the FR that can be drilled via PT to access the RW. This approach is an optimal consensus route for safe and effective electrode insertion during CI. Although it is still associated with the possible risk of FN and chorda tympani nerve injury, it is considered the safest approach during CI. Beforehand surgical planning using the HRCT could help avoid the associated risk and allow the surgeon to prepare for possible intraoperative difficulties.<sup>10-12</sup>

Previous studies tried to detect anomalies related to the VPFFN course. Sennaroglu et al found that the coronal cuts of the HRCT are necessary to assess the relationship between the middle ear windows and the FN.<sup>13</sup> Usually, at the level of the oval window (OW), the horizontal portion of the FN is found below the LSC. At the level of the RW, the VPFFN is seen below the LSC and is more lateral compared to the OW section. Anterior displacement of the VPFFN occurs if the tympanic portion is seen at the OW and RW cuts, where a horizontal portion usually would be. On the other hand, generally, at the axial cut showing the basal turn of the cochlea and the RW at the FR, the horizontal part of the FN can be seen, and there is usually a space between this and the EAC. Lateral displacement of the VPFFN occurs if the nerve is located directly below the EAC. In this case, the standard

procedure may be more challenging. This description of the VPFFN course displacement is complicated and needs coronal and axial images without clear landmarks. They did not evaluate the feasibility of this radiological method to detect VPFFN course anomalies and their impact on CI surgery.

Telmesani et al made an outstanding classification of the location of the VPFFN and its relationship to the most lateral part of the LSC in coronal sections of the HRCT.<sup>8</sup> They included 140 patients in their retrospective observational study. They found that type I when the VPFFN was located medial to the most lateral part of the LSC, was present in 97 (69%) ears. Type II, when the VPFFN was situated at the same level as the most lateral part of the LSC, was present in 25 (18%) ears. Furthermore, when the VPFFN was located lateral to the most lateral aspect of the LSC, type III was present in 18 (13%) ears. Telmesani et al study showed a significant correlation between the VPFFN location and the approach used to access the RW during CI operation. There was no correlation between the VPFFN location and age or the inner ear anomalies. In 4 cases with lateral displacement of the VPFFN (type III), the operator had to change the traditional PT route and elevate the tympanomeatal flap to access the RW for electrode insertion. Although this classification was obvious and used fixed landmarks in addition to evaluating its impact on CI surgery, it only assesses the VPFFN location in the medial-to-lateral dimension.

In contrast, Mandour et al were concerned with evaluating the VPFFN displacement in the posterior-to-anterior dimension.<sup>9</sup> They assessed the VPFFN location about the limbs of the LSC in the coronal views of the HRCT. They evaluated the effect of anterior displacement of the VPFFN on RW visibility during CI surgery. Their retrospective observational study included 246 patients. They found that type I VPFFN, when the VPFFN was behind the posterior limb of the LSC, was in 84 (34%) patients. While type II VPFFN, when the VPFFN was anterior to the posterior limb of the LSC but posterior to the anterior limb of the LSC, was present in 149 (61%) cases. Furthermore, type III VPFFN, when the VPFFN was at the same extent or anterior to the anterior limb of the LSC, was present in 13 (5%) cases. This radiological classification significantly correlated with the RW accessibility with an accuracy of 98%. In 11 cases of type III VPFFN, RW accessibility

was achieved after extrasurgical interventions of the traditional PT approach. Although this classification was very effective in detecting the anterior displacement of the VPFN, it was limited to only 1 dimension, the posterior-to-anterior dimension.

Although both the anterior and lateral displacement of the VPFN may affect the RW accessibility, Elzayat et al found that the PT difficulty was statistically related more to the lateral displacement of the VPFN in their radiological analysis of the FR and evaluating its impact on the CI surgery.<sup>14</sup>

For more precise preoperative radiological localization of the VPFN, we proposed a comprehensive classification of the VPFN location in both directions, the medial-to-lateral and posterior-to-anterior dimensions, incorporating the previous classifications of Telmesani et al and Mandour et al. We believed that this classification of the VPFN would provide the CI surgeon with the accurate location of the VPFN using only 1 HRCT plane, the coronal plane, with an easily applicable method. In addition, we used a fixed, unmistakable landmark, the LSC, which most CI surgeons and radiologists can easily detect.

Type A VPFN indicated an average position of the VPFN in both dimensions. Type B VPFN meant the anterior displacement of the VPFN with an average position in the medial-to-lateral dimension. Type C VPFN indicated the lateral displacement of the VPFN with an average position in the posterior-to-anterior dimensions. Finally, type D VPFN refers to the displacement of the VPFN in both dimensions.

We found a statistically significant correlation between this classification and intraoperative RW accessibility, which entails visibility and instrument manipulation. Most cases with type C VPFN and all with type D VPFN required extrasurgical interventions to access the RW for the electrode insertion. Furthermore, in 2 cases of the last type, accessibility was impossible because of VPFN displacement, and the surgeon may use the retrofacial route to access the RW. This classification had an accuracy of 90.42%, so it is dependable in the preoperative prediction of RW accessibility. In patients with predicted difficult visibility to the RW, the surgeon would plan for extrasurgical interventions or use another approach. Also, he or she can prepare the oto-endoscopy and other needed instruments.

### Study Limitations

Future prospective studies that include variable age groups may be needed to increase the validity of this proposed classification.

We suggested a radiological categorization of the VPFN location, combining the previous classifications by Telmesani and Mandour. This classification could provide the surgeon preoperatively with the precise location of the VPFN in the lateral-to-medial and the posterior-to-anterior dimensions using only the coronal plane of the HRCT in a straightforward method. Furthermore, this radiological localization of the VPFN had a significant relationship with intraoperative RW visibility through the PT approach during CI, with an accuracy of 90.42%. Therefore, types C and D were expected to have difficulty accessibility into the RW, and more surgical interventions were needed to modify the PT to achieve RW accessibility. In addition, other approaches, such as the retrofacial approach, may be used in cases with impossible RW accessibility, especially in type D VPFN.

**Ethics Committee Approval:** The study was approved by the Institution Review Board of Tanta University (Approval No: 35731/9/22).

**Informed Consent:** Informed consent was obtained from all subjects and their parents involved in the study.

**Peer-review:** Externally peer-reviewed.

**Author Contributions:** Concept – M.F.M.; Design – M.F.M.; Supervision – M.A.; Resources – S.E.; Materials – E.C.; Data Collection and/or Processing – M.B.; Analysis and/or Interpretation – R.L.; Literature Search – H.H.F.; Writing – H.H.F.; Critical Review – M.T.

**Declaration of Interests:** The authors have no conflict of interest to declare.

**Funding:** The authors declared that this study has received no financial support.

### REFERENCES

1. Mandour MF, Khalifa MA, Khalifa HMA, Amer MAR. Iatrogenic facial nerve exposure in cochlear implant surgery: incidence and clinical significance in the absence of intra-operative nerve monitoring. *Cochlear Implants Int.* 2019;20(5):250-254. [\[CrossRef\]](#)
2. Mandour M, Elfaragy HH, Lotfy R, Elsheikh MN, Barbara M, Elzayat S. A novel radiological method to evaluate the posterior tympanotomy depth for cochlear implantation: our experience in 257 patients. *Eur Arch Otorhinolaryngol.* 2022;279(10):4893-4898. [\[CrossRef\]](#)
3. Jwair S, van Eijden JJM, Blijleven EE, Dankbaar JW, Thomeer HGXM. Radiological and surgical aspects of round window visibility during cochlear implantation: a retrospective analysis. *Eur Arch Otorhinolaryngol.* 2022;279(1):67-74. [\[CrossRef\]](#)
4. Song JJ, Park JH, Jang JH, et al. Facial nerve aberrations encountered during cochlear implantation. *Acta Otolaryngol.* 2012;132(7):788-794. [\[CrossRef\]](#)
5. Yilmazer R, Gerring RC, Sidani C, Wolfowitz A, Angeli SI, Telischi FF. The feasibility of retrofacial approach for cochlear implantation. *Otol Neurotol.* 2018;39(7):e550-e556. [\[CrossRef\]](#)
6. Ren B, Bai P, Li T, et al. Anatomic landmarks for localization of the vertical segment of facial nerve on multislice CT multiplanar reconstruction images. *J Craniofac Surg.* 2015;26(7):2193-2195. [\[CrossRef\]](#)
7. Rajati M, Afzalzadeh MR, Nourizadeh N, Ghasemi MM, Zandi B. Predicting round window visibility by HRCT during cochlear implantation in children. *Cochlear Implants Int.* 2020;21(5):269-274. [\[CrossRef\]](#)
8. Telmesani LM, Alrammah MK. Telmesani radiological classification of the location of the vertical segment of the facial nerve: impact on surgical approach in cochlear implant surgery. *Otol Neurotol.* 2017;38(9):e335-e338. [\[CrossRef\]](#)
9. Mandour M, Elzayat S, Elfaragy HH, Lotfy R, ElNaggar A. Radiological classification of the mastoid portion of the facial nerve: impact on the surgical accessibility of the round window in cochlear implantation. *Acta Otolaryngol.* 2021;141(9):894-897. [\[CrossRef\]](#)
10. Kim CW, Oh SJ, Kim HS, Ha SH, Rho YS. Analysis of axial temporal bone computed tomography scans for performing a safe posterior tympanotomy. *Eur Arch Otorhinolaryngol.* 2008;265(8):887-891. [\[CrossRef\]](#)
11. Aristegui M, Martín-Oviedo C, Aristegui I, García-Leal R, Ruiz-Juretschke F. Anatomical variations of the intrapetrous portion of the facial nerve. *Anat Rec (Hoboken).* 2019;302(4):588-598. [\[CrossRef\]](#)
12. Widmann G, Dejaco D, Luger A, Schmutzhard J. Pre- and post-operative imaging of cochlear implants: a pictorial review. *Insights Imaging.* 2020;11(1):93. [\[CrossRef\]](#)
13. Sennaroglu L. Cochlear implantation in inner ear malformations--a review article. *Cochlear Implants Int.* 2010;11(1):4-41. [\[CrossRef\]](#)
14. Elzayat S, Mandour M, Elfaragy HH, et al. Radiological analysis of the facial recess: impact on posterior tympanotomy difficulty during pediatric cochlear implantation. *Otolaryngol Head Neck Surg.* 2022;167(4):769-776. [\[CrossRef\]](#)