

Erratum

In the article by Kajiwara et al., entitled "Bilateral Nontuberculous Mycobacterial Otitis Media: A Case Report", that was published in the January issue of The Journal of International Advanced Otology (J Int Adv Otol.2024;20(1):81-84; DOI: 10.5152/iao.2024.231187), figures 2A and 2B were incorrectly added to the file. The updated figure is as follows:

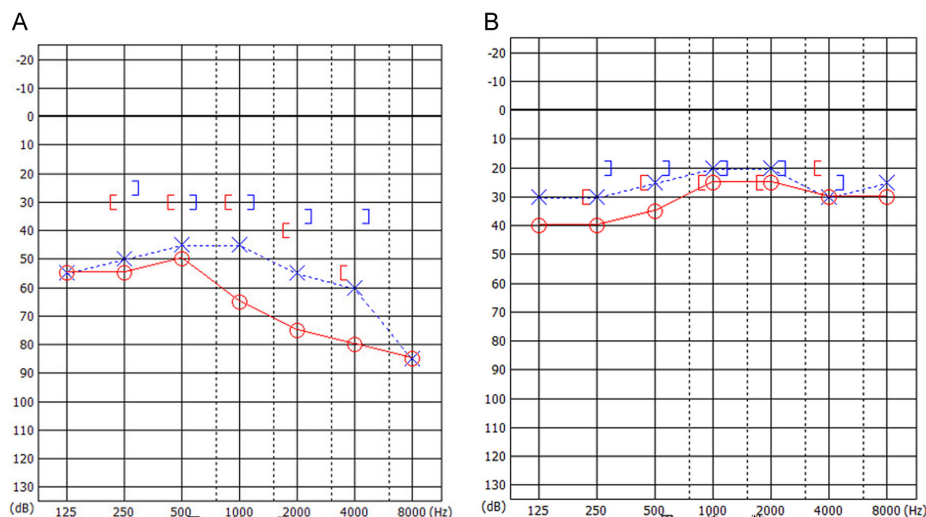


Figure 2. Audiometric findings. A) At the initial visit, pure-tone audiometry revealed bilateral mixed conductive–sensorineural hearing loss with 63.8 dB in the right ear and 47.5 dB in the left ear. B) After the treatment, air conduction hearing improved in both ears.

You may access the updated version of the article via the link below.

<https://www.advancedotology.org/en/bilateral-nontuberculous-mycobacterial-otitis-media-a-case-report-163852>