



## Case Report

# Inflammatory Myofibroblastic Tumors of the Middle Ear: An Unpredictable and Aggressive Disease

Jae-Gu Cho, Naree Lee, Ik One Yoo, Sung-Won Chae

Department of Otorhinolaryngology-Head and Neck Surgery, Korea University Faculty of Medicine, Seoul, Korea

Inflammatory myofibroblastic tumour is a rare disorder of unknown aetiology first described in the lung. Inflammatory myofibroblastic tumour of the middle ear accounts for only a small portion of this disease and tends to have a more aggressive and unpredictable course than the disease at other sites of the body. Fewer than 20 cases of inflammatory myofibroblastic tumour of the middle ear have been reported in the English literature thus far. We present a case of inflammatory myofibroblastic tumour in a 46-year-old man with unilateral hearing loss. Computed tomography (CT) imaging showed dehiscence of the promontory. Initial biopsy failed to diagnosis the disease, as in many other cases we reviewed. The mass was extensive and eroded several cortical bony structures. The patient underwent radical mastoidectomy and final pathology exam confirmed the diagnosis. We review the key radiological and histological results that should be considered for making a diagnosis of inflammatory myofibroblastic tumour, and discuss the possible differential diagnosis. We also present a review of previously reported cases to help better understand the clinical entity of this disease.

**KEY WORDS:** Inflammatory pseudotumour, inflammatory myofibroblastic tumour, temporal bone

## INTRODUCTION

The term 'inflammatory myofibroblastic tumour' (IMT) and its definition were first formalised in 1990 by the World Health Organization (WHO), stated as "a tumour composed of differentiated myofibroblastic spindle cells usually accompanied by numerous plasma cells and/or lymphocytes"<sup>[1]</sup>. Earlier reports used terminology such as inflammatory pseudotumour, plasma cell granuloma, pseudo-sarcomatous myofibroblastic proliferation, myofibroblastoma, xanthomatous pseudotumour, and atypical fibromyxoid nodule to describe this disease. It has been found in every part of the body, most commonly in the lungs. The upper respiratory tract such as the larynx, trachea, oropharynx, and nasopharynx accounts for 11% of extra-pulmonary lesions. The head and neck area accounts for less than 5% of all cases<sup>[2]</sup>. The orbit is the most commonly encountered site in this area. After performing a review of the English literature, we identified 16 cases reported in the middle ear and/or temporal bone. The clinical behaviour of IMT occurring in the middle ear cavity is not yet clear. Additionally, no established guideline for diagnosis or treatment exists. Diagnosis is by exclusion. Treatment options are radical surgery, high-dose steroids, and radiation therapy, according to individual tumour location, size, and extension.

Here, we report a case of middle ear IMT with an aggressive behaviour, showing extension to the otic capsule and carotid canal. We describe the clinical features, radiological and pathological findings, and outcome. We also present previous reported cases after conducting a review of the English literature.

## CASE REPORT

A 46-year-old male presented with a 5-year history of progressive left side hearing loss. His hearing loss was not associated with discharge, tinnitus, or vertigo. He also denied any history of previous ear infections. Past medical history was unremarkable. Otolological examination revealed a firm, hard, and non-tender mass in the left external auditory canal compared with the normal right external auditory canal and tympanic membrane (Figures 1a and 1b). It was a soft tissue mass lesion rather than a cholesteatoma. Pure tone audiometry revealed profound sensorineural hearing loss in the left ear. Computed tomography of the temporal bone and magnetic resonance imaging showed a soft tissue mass with ill-defined borders in the left middle ear and the external ear canal. Bony erosion was noted adjacent to the carotid canal, cochlear basal turn, and the ossicles (Figures 1c and 1d). A biopsy taken at the initial visit showed necrotic and degenerated tissue only.

The patient underwent radical mastoidectomy with tumour removal. During the operation, it was found that the tumour mass filled the entire mastoid space and middle ear cavity. Total bony erosion was noted at the carotid canal and care was taken

### Corresponding Address:

Sung-Won Chae, Department of Otorhinolaryngology-Head and Neck Surgery, Guro Hospital, Korea University College of Medicine, 80 Guro-dong, Guro-gu, Seoul 152-703, South Korea Phone: 82-2-2626-3186; Fax: 82-2-868-0475; E-mail: schae@kumc.or.kr

Submitted: 19.08.2013 Accepted: 22.12.2013

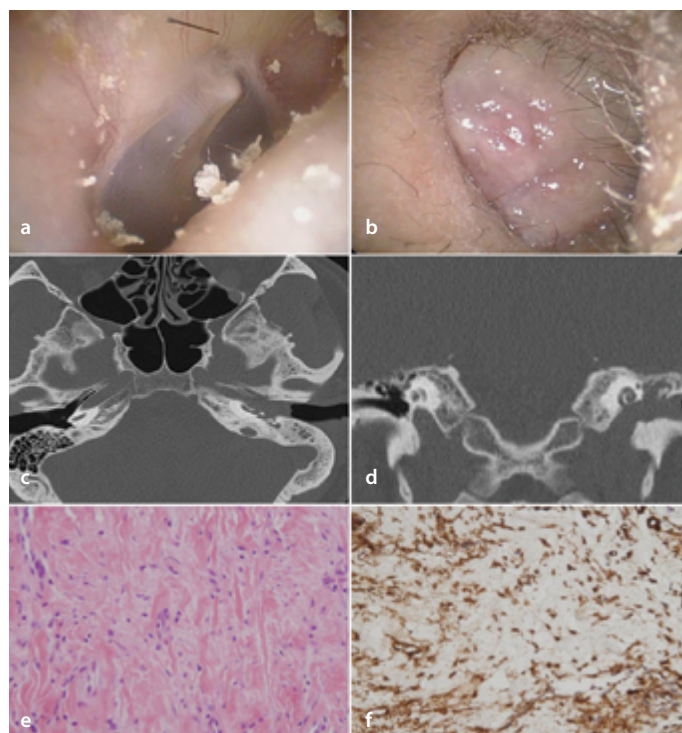
not to injure the carotid artery. The malleus and incus were partially eroded and stapes was totally missing; the promontory was also eroded, resulting in dehiscence of the otic capsule. The malleus and incus were removed. The promontory dehiscence site was obliterated by palva flap. Intra-operative frozen biopsy examination was suspicious for haemangioma. However, final histopathological report showed spindle cell proliferative lesion with heavy collagen deposition, low mitotic count, minimal nuclear atypia, and background inflammation (Figure 1e). Abundant small-sized vessels were present in the periphery of the lesion. The spindle cells stained positive for beta-catenin and smooth muscle actin (SMA), but were negative for anaplastic lymphoma kinase (ALK) (Figure 1f). The lesion was confirmed to be IMT. During the post-operative 10-month period, there was no sign of recurrence, and the patient remains symptom free.

## DISCUSSION

Inflammatory myofibroblastic tumour of the middle ear is a rare lesion. IMT was regarded as 'pseudotumour' in the past, but it is now recognised to be true neoplasm. In the head and neck region, the orbit is the most commonly involved site, accounting for 8-17% of all orbital tumours [3]. Although clinical characteristics can be gathered from orbital IMTs, the middle ear space is a much smaller cavity than the orbit, surrounded by bone and inner ear structure, making the disease progression and choice of treatment rather different from those of the orbit.

It is generally known that middle ear IMTs have a more aggressive and unpredictable course. Bone erosion and extension to adjacent structures are common, as occurred in the present case, resulting in dehiscence of the otic capsule. Williamson et al. [4] reported in their case and literature review 10 cases of inflammatory pseudotumour in the middle ear and/or temporal bone from the period of 1967 to 2002. In this review, 7 cases (70%) reported bone erosion by the tumour. The most commonly involved structures were the mastoid, ossicles, tegmen, otic capsule, and labyrinth. Residual and/or recurrent disease occurred in 2 cases (20%). One of the recurred cases reported radiation therapy (5000 cGy in total) to be an effective treatment [5]. In both cases, recurrence occurred within a 12-month period.

We performed a review of the English literature by searching the National Library of Medicine Pubmed online database using the terms 'inflammatory myofibroblastic tumour' and 'inflammatory pseudotumour' from 2003 to the present. We identified six reported cases of IMT during this period [6-11]. There was a slight male dominant tendency (four cases), and the patients' age varied from 7 to 75 years. The gross appearance typically shows a smooth surface with a polypoid or nodular appearance. The colour is usually pale pinkish and the consistency firm to rubbery. Bleeding or necrosis is not prominent. Bone erosion was reported in five cases; the only case without erosion of the bone was a case of a 7-year-old girl [6]. Tegmen tympani dehiscence occurred in two cases, otic capsule involvement occurred in one case, and facial nerve palsy was reported in one case. Choice of treatment was surgical removal in most of the cases. Galindo et al. [7] reported a case of IMT that involved the lateral clivus and petrous bone. An infracochlear approach was adopted to open the petrous apex and successfully remove the lesion. Coulsen et al. [8] reported a case of IMT filling the middle ear, with gross involvement of the dura



**Figure 1.** a-f. Inflammatory myofibroblastic tumour of the left middle ear. Normal right tympanic membrane (a). Tumour obstructing the left external auditory canal (b). Axial computed tomography scan showing soft tissue density in the left middle ear cavity and bony dehiscence of the carotid canal and promontory (c). Coronal computed tomography scan (d). Hematoxylin and Eosin staining (x200 magnification) showing fibroblastic proliferation and spindle cells accompanied by infiltration of plasma cells and lymphocytes (e). Positive staining for smooth muscle actin (x100 magnification) (f)

and symptom of facial nerve palsy (House-Brackman grade II). Both the lesion and symptom showed complete remission after oral steroid treatment only, without complete excision. The patient remains symptom free, with no sign of recurrence. One case of recurrence was reported by Francisco et al. [9]. In this case, the lesion was initially mistaken as chronic otitis media.

Among the imaging studies, magnetic resonance imaging is a relatively useful study. IMT shows low signal intensity in T2-weighted images and homogenous enhancement on T1-weighted images. Marked contrast enhancement can be mistaken for hypervascular lesions such as glomus tumour, but IMTs lack the typical permeative bone change. Hypointensity can be explained by the relative lack of mobile protons in the fibrotic tissue. However, it can also indicate elevated cellularity or high nuclear to cytoplasm ratio, typical of malignant neoplasm [10]. According to previous reports, it is difficult to differentiate an infiltrating temporal bone lesion between aggressive IMT and malignant neoplasm [11].

On pathological examination, tumours and tumour-like conditions composed of myofibroblasts and fibroblasts should be differentiated with IMT because of a similar morphological appearance. The less cellular component of IMT can be mistaken for aggressive fibromatosis, but the prominent inflammation of IMT is the critical distinguishing point. The lack of significant cellular atypia in IMT cells help to differentiate IMT from fibrosarcoma or other spindle cell tumours [12].

In conclusion, inflammatory myofibroblastic tumors of the middle ear and/or temporal bone is a rare and locally destructive lesion. It can be distinguished from cholesteatoma by gross appearance. Frozen biopsy results can be equivocal and misleading, such as in our case. Surgeons operating on the temporal bone should keep a high suspicion when they encounter a granulation-like mass lesion with prominent inflammation and extensive erosion of surrounding bony structures. Surgery is the mainstay of treatment; complete excision with free margin is important. If complete surgical excision is unsuccessful or impossible, high-dose steroid is reported to show a good response. Reported recurrence occurred within a year after surgical treatment, so frequent follow-up during this period is required.

**Informed Consent:** Written informed consent was obtained from patient who participated in this study.

**Peer-review:** Externally peer-reviewed.

**Author Contributions:** Concept - S.W.C.; Design - J.G.C.; Supervision - S.W.C.; Data Collection and/or Processing - N.L., I.O.Y.; Literature Review - J.G.C.; Writing - J.G.C.; Critical Review - S.W.C.

**Conflict of Interest:** No conflict of interest was declared by the authors.

**Financial Disclosure:** The authors declared that this study has received no financial support.

## REFERENCES

1. Weiss SW. Miscellaneous tumors. In: Weiss SW, Sobin LH, Enzinger FM, editors. *Histological typing of soft tissue tumors*. 2nd ed., Berlin: Springer-Verlag; 1994. p.48. [\[CrossRef\]](#)
2. C.M. Coffin, J. Watterson, J.R. Priest, L.P. Dehner, Extrapulmonary inflammatory myofibroblastic tumor (inflammatory pseudotumor). A clinicopathologic and immunohistochemical study of 84 cases, *Am. J. Surg. Pathol.* 1995; 19: 859-72. [\[CrossRef\]](#)
3. Uy HS, Nguyen QD, Arbour J, Gravel M, D'Amico DJ, Jakobiec FA, et al. Sclerosing inflammatory pseudotumor of the eye. *Arch Ophthalmol* 2001; 119: 603-7. [\[CrossRef\]](#)
4. R.A. Williamson, PPaueksakon, N.J. Coker, Inflammatory pseudotumor of the temporal bone. *Oto INeurotol* 2003; 24: 818-22. [\[CrossRef\]](#)
5. Cho YS, Kim SM, Chung WH, Hong SH. Inflammatory pseudotumor involving the skull base and cervical spine. *J Laryngol otol* 2001; 115: 580-4. [\[CrossRef\]](#)
6. Lee DH, Shin OR, Cho KJ, Kim JH. Inflammatory pseudotumor in the middle ear cavity. *Int J Pediatr Otorhinolaryngol.* 2008; 72: 1569-72. [\[CrossRef\]](#)
7. Galindo J, Lassaletta L, Garcia E, Gavilan J, Allona M, Royo A, Patrón M. Spontaneous hearing improvement in a patient with an inflammatory myofibroblastic tumor of the temporal bone. *Skull Base.* 2008; 18: 411-5. [\[CrossRef\]](#)
8. Coulson C, George A, Biswas A, Phelan C, De R. Pseudotumour of the temporal bone: an unusual cause of otorrhoea and facial palsy *Eur Arch Otorhinolaryngol.* 2008 Jun;265(6):713-5. Erratum in: *Eur Arch Otorhinolaryngol.* 2008; 265: 733. [\[CrossRef\]](#)
9. Santaolalla-Montoya F, Ere-o C, Zabala A, Carrasco A, Martínez-Ibargüen A, Sánchez-Fernández JM. Inflammatory myofibroblastic tumor of the temporal bone: a histologically nonmalignant lesion with fatal outcome. *Skull Base.* 2008; 18: 339-43. [\[CrossRef\]](#)
10. Gasparotti R, Zanetti D, Bolzoni A, Gamba P, Morassi ML, Ungari M. *AJNR* Inflammatory myofibroblastic tumor of the temporal bone. *Am J Neuro-radiol.* 2003; 24: 2092-6.
11. Cho KJ, Lee DH, Jung SH, Kim JH. A case of an inflammatory myofibroblastic tumor of the mastoid presenting with chronic suppurative otitis media. *Auris Nasus Larynx.* 2007; 34: 523-6. [\[CrossRef\]](#)
12. Lawrence B, Perez-Atayde A, Hibbard MK, Rubin BP, Dal Cin P, Pinkus JL, et al. TPM3-ALK and TPM4-ALK oncogenes in inflammatory myofibroblastic tumors. *Am J Pathol.* 2000; 157: 377-84. [\[CrossRef\]](#)